



GUIDELINES

Viewpoints, pertaining to issues of general interest, are welcome, even if they are not related to items previously published. Viewpoints may present unique techniques, brief technology updates, technical notes, and so on. Viewpoints will be published on

a space-available basis because they are typically less time-sensitive than Letters and other types of articles. Please note the following criteria:

- Text—maximum of 500 words (not including references)
- References—maximum of five
- Authors—no more than five
- Figures/Tables—no more than two figures and/or one table

Authors will be listed in the order in which they appear in the submission. Viewpoints should be submitted electronically via PRS' *enkwel*, at www.editorialmanager.com/prs/. We strongly encourage authors to submit figures in color.

We reserve the right to edit Viewpoints to meet requirements of space and format. Any financial interests relevant to the content must be disclosed. Submission of a Viewpoint constitutes permission for the American Society of Plastic Surgeons and its licensees and assignees to publish it in the *Journal* and in any other form or medium.

The views, opinions, and conclusions expressed in the Viewpoints represent the personal opinions of the individual writers and not those of the publisher, the Editorial Board, or the sponsors of the *Journal*. Any stated views, opinions, and conclusions do not reflect the policy of any of the sponsoring organizations or of the institutions with which the writer is affiliated, and the publisher, the Editorial Board, and the sponsoring organizations assume no responsibility for the content of such correspondence.

Viewpoints

The Transcaruncular-Transnasal Suture: A Simple Technique for Medial Canthopexy

Sir:

Telecanthus or displacement of the medial canthus (e.g., after trauma or in congenital craniofacial deformities involving the naso-orbitoethmoidal complex) disturbs facial harmony. Different procedures have been described for its correction.¹⁻³ However, medial canthopexy has the inherent risk of relapse because, from the periosteal side, the correct localization of the medial canthal tendon with sufficient grip is difficult to achieve.

To improve the simplicity and reliability of medial canthopexy, a transcaruncular-transnasal fixation technique was developed. By means of a bicoronal approach to the naso-orbitoethmoidal complex, the soft tissue is completely detached and extensively mobilized at the medial orbit and the upper and lower orbital rims, including the dystopic medial canthal tendon.

After bony reconstruction or reshaping of the naso-orbitoethmoidal complex, the medial canthal tendon is re-attached using 0 polydioxanone suture with a CT needle. The surface of the periosteum (i.e., tenon capsule) is rougher where the medial canthal tendon is fixed to the bone, but it may be difficult to localize in cases of secondary reconstruction. The needle is inserted from the posterior edge of this rough area and pushed laterally through the caruncula skin surface (Fig. 1). The suture is partially pulled through. Then, the needle is reinserted into the caruncula and pushed in the opposite direction, aiming again for the rough surface but in a slightly diverting way to ensure adequate soft-tissue grip (Fig. 1). The suture is pulled tight to check its effectiveness. The suture placing guarantees that the lacrimal duct and the canaliculi lacrimales are located anterior and the eye muscles lateral (Fig. 1) as it grasps the posterior ligament of the medial canthal tendon. Both suture ends are passed through the papyraceous part of the ethmoid bone to the opposite medial orbit. The second transcaruncular medial canthopexy is performed. The needle is fed back through the transnasal hole, and now both ends of the suture are pulled tight, narrowing the medial canthi and the surrounding periorbital soft tissue.

In malformations, the nasal and medial orbital bones are lifted off and the suture is placed behind this bone segment. It is put back and the ends of the sutures are threaded through bore holes at the supraorbital rim and knotted after tightening. The technique can also be used on one eye only, with the suture being anchored and tightened on the contralateral side of the frontal bone.

In trauma patients ($n = 4$), the intercanthal distance was narrowed from 41 mm on average to 38.5 mm following surgery; and in patients with congenital craniofacial deformities (frontoethmoidal meningoencephaloceles $n = 9$), the intercanthal distance was narrowed from 45.1 mm on average to 36.6 mm following surgery (Fig. 2). No postoperative complications were encountered.

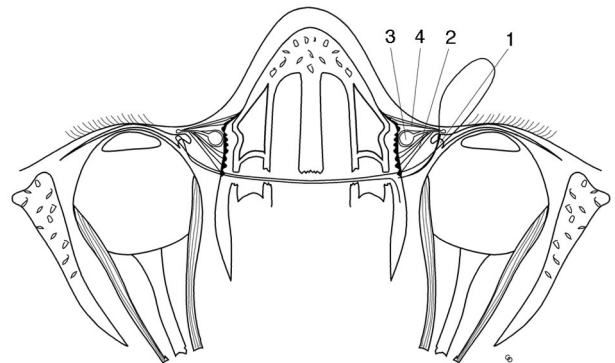


Fig. 1. Schematic drawing (cross-section) of the anatomy of the naso-orbitoethmoidal region, with the medial canthal tendon demonstrating the placement of the transcaruncular transnasal suture (1, caruncula; 2, posterior ligament of the medial canthal tendon; 3, lacrimal sac with canaliculi; 4, anterior ligament of the medial canthal tendon).

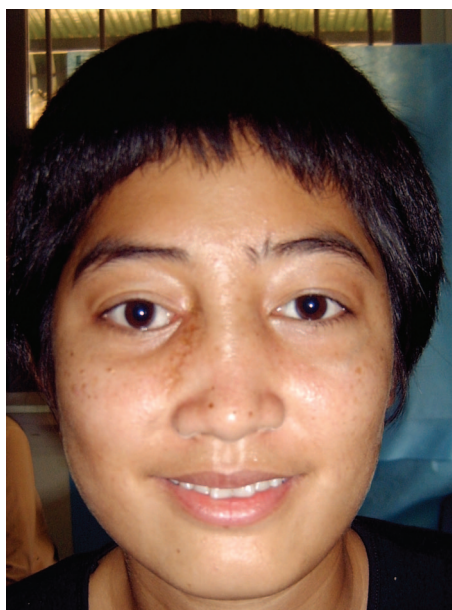

Fig. 2. Patient with a frontoethmoidal meningoencephalocele after internal resection of the meningoencephalocele by means of a bicoronal approach and immediate reconstruction of the naso-orbitoethmoidal region using the transcaruncular-transnasal suture for bilateral medial canthopexy.

The transcaruncular-transnasal suture is a simple technique for reliably facilitating medial canthopexy. Especially in malformation surgery⁴ and in primary or secondary reconstruction⁵ after trauma, medial canthopexy by means of the transcaruncular suture provided a safe anchorage in the soft tissue and in the bone of the orbital rim. It does not interfere with delicate structures of the lacrimal duct system but instead allows for the ideal direction of pulling, ensuring anatomically correct reshaping of the medial canthus.

DOI: 10.1097/PRS.0b013e318186cadf

Günter Lauer, M.D., Ph.D.

Department of Oral and Maxillofacial Surgery

Thomas Pinzer, M.D.

Department of Neurosurgery
University Hospital Carl Gustav Carus Dresden
Technical University Dresden
Dresden, Germany

Correspondence to Dr. Lauer
Department of Oral and Maxillofacial Surgery
University Hospital Carl Gustav Carus Dresden
Technical University
Fetscherstraße 74
D-01307, Dresden, Germany
guenter.lauer@uniklinikum-dresden.de

DISCLOSURES

Operations on patients with malformations were performed in Phnom Penh, Cambodia. Traveling costs for the surgeons (T.P. and G.L.) were funded by the charity organization Ärzte der Welt Deutschland e. V. There were

no commercial associations or financial relationships that might pose or create a conflict of interest with information presented in this article.

REFERENCES

1. Zide, M. F., and McCarthy, J. G. The medial canthus revisited: An anatomical basis for canthopexy. *Ann. Plast. Surg.* 11: 1, 1983.
2. Kelly, C. P., Cohen, A. J., Yavuzer, R., Moreira-Gonzalez, A., and Jackson, I. T. Medial canthopexy: A proven technique. *Ophthalm. Plast. Reconstr. Surg.* 20: 337, 2004.
3. Moe, K. S., and Kao, C. H. Precaruncular medial canthopexy. *Arch. Facial Plast. Surg.* 7: 244, 2005.
4. Lauer, G., Pinzer, T., and Gollogly, J. Plastisch-rekonstruktive Behandlung von Patienten mit frontoethmoidalen Meningoencephalozelen in der Dritten Welt. *J. D.G.P.W.* 30: 14, 2004.
5. Lauer, G., Pradel, W., Schneider, M., and Eckelt, U. Efficacy of computer assisted surgery in secondary orbital reconstruction. *J. Craniomaxillofac. Surg.* 34: 299, 2006.

Complex Nasal Reconstruction: Improving Accuracy with the Use of Reverse-Engineered Three-Dimensional Surgical Guides

Sir:

We have sought strategies to enhance our ability to successfully reconstruct the human nose. We present here one of our efforts to use current technology to improve our ability to accurately create the sub-surface framework on which the success of such an endeavor rests. This novel approach developed by the authors involves the creation of an intraoperative surgical guide, aided by three-dimensional laser surface scanning and rapid prototyping. This translucent template is developed through cooperative effort by the patient, anaplastologist, and surgeon working together. It is custom made, sterilized, and placed on the patient's face at critical points during the procedure. The subsurface framework is then painstakingly built in a stable fashion to reflect the dimensions and contour of this guide. It is created in such a manner as to anticipate

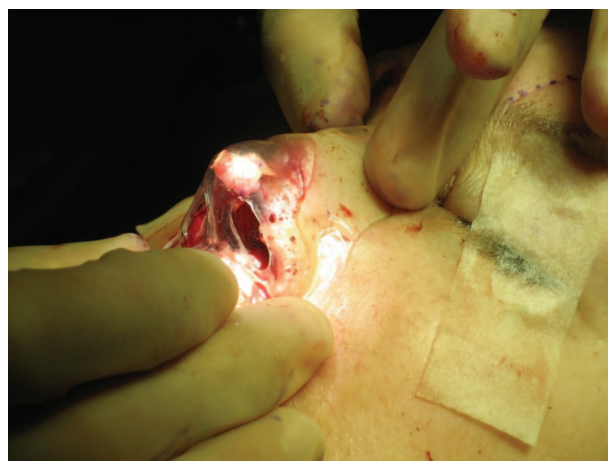

Fig. 1. Surgical guide during intraoperative use.

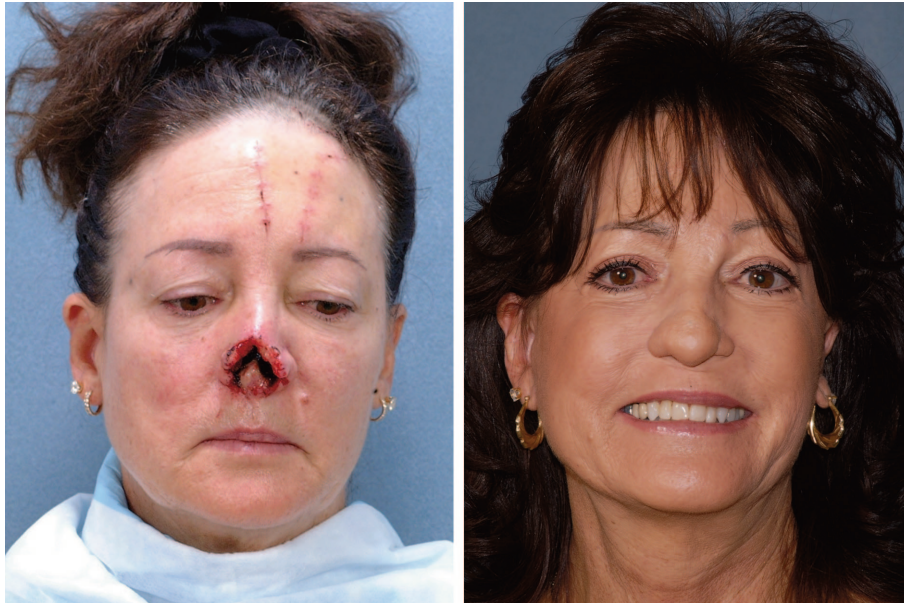

Fig. 2. (Left) A patient with a defect after resection of intranasal carcinoma and before radiation therapy. (Right) Appearance 1 year after reconstruction.

the effect of the thickness of the forehead flap on the final external dimensions.

Because the primary utility of this is for the creation of the subsurface cartilaginous framework, it is used in patients with full-thickness, complex defects of the nasal tip. The anaplastologist takes an impression. The model is sculpted using wax with the aid of presurgical photographs. The model is then sent to Direct Dimensions, Inc. (Owings Mills, Md.), for surface scanning, digital manipulations of the resulting three-dimensional file, and final output.

The template is digitally offset down from the external surface contour to account for the eventual placement of the paramedian forehead flap over the subsurface framework. The rapid prototype output is duplicated by casting silicone putty material as a negative into the rapid prototype output. A 1.5-mm-thick thermoforming clear material is then vacuformed over the negative model. Templates are delivered to the surgeon along with instructions for cold sterilization.

The provision of well-vascularized, thin lining tissue is achieved by a variety of methods, depending on the individual patient's needs. The clear intraoperative guide is used exclusively for the creation of the rigid cartilaginous framework of the nose. The creation of the nasal tip proceeds from the base of the columella to the tip-defining points. Once the initial structure is created, additional layers of cartilage micrografts are then meticulously suture fixated in another layer, where needed. The template is placed on the patient's face as a guide multiple times throughout this process to check the projection of the reconstructed cartilaginous framework (Fig. 1). The goal is to perfectly fill in the spaces on the undersurface of the clear template. Once the framework is structurally sound and the tem-

plate rests comfortably over the framework like a glove, this portion of the procedure is complete. The paramedian forehead flap procedure then follows (Fig. 2).

To our knowledge, this is the first report of the use of custom-made, three-dimensional, translucent intraoperative surgical guides for nasal reconstruction. We have found value in improving the predictable accuracy of performing one component of nasal reconstruction: the creation of a subsurface framework of an appropriate size, shape, and contour. The guide is translucent, can be sterilized, and is custom fit to the patient's facial contour. The template functions as a tactile and visual reference that compels the surgeon to sculpt the tip in all its detail and assists in the achievement of stability and completeness of the nasal reconstruction. DOI: 10.1097/PRS.0b013e318186caa2

Patrick J. Byrne, M.D.

Division of Facial Plastic and Reconstructive Surgery
Department of Otolaryngology–Head and Neck Surgery
The Johns Hopkins University School of Medicine

Juan R. Garcia, M.A.

Department of Art as Applied to Medicine
The Johns Hopkins University
Baltimore, Md.

Correspondence to Dr. Byrne
Department of Otolaryngology–Head and Neck Surgery
The Johns Hopkins University School of Medicine
601 North Caroline Street, 6th Floor
Baltimore, Md. 21287
pbyrne2@jhmi.edu

DISCLOSURES

Juan Garcia discloses that Direct Dimensions, Inc., provides him with office space free of charge because of his

continued collaborations with them. He discloses that he is not a paid consultant with them. Otherwise, the authors verify that they have no financial interests, commercial associations, or conflicts of interest to disclose.

Ninety-Degree Transposed Free Jejunal Patch Transfer for Hypopharyngeal Reconstruction following Partial Hypopharyngectomy

Sir:

Noncircumferential hypopharyngeal defects following partial hypopharyngectomy with preservation of the larynx have been reconstructed with free jejunal patch grafts or forearm flaps.¹⁻³ Conventionally, the free jejunal patch graft was transferred in an isoperistaltic fashion (Fig. 1), but pooling of food was occasionally seen because of the peristaltic constriction and circular folds of the jejunum. To overcome this disadvantage, we transferred the jejunal patch in a 90-degree transposed fashion, positioning the oral side of the jejunum in correspondence with the anterior side of the defect (Figs. 1 and 2).

Between August of 2004 and January of 2006, six patients underwent free jejunal patch transfer using our new procedure at the University of Tokyo Hospital. This was the study group and consisted of six men aged 57 to 64 years (average, 60 years). Before this term, seven patients underwent the operation with the conventional method. This was the control group and consisted of one woman and six men aged 50 to 75 years (average, 63 years). During cancer ablation, the superior

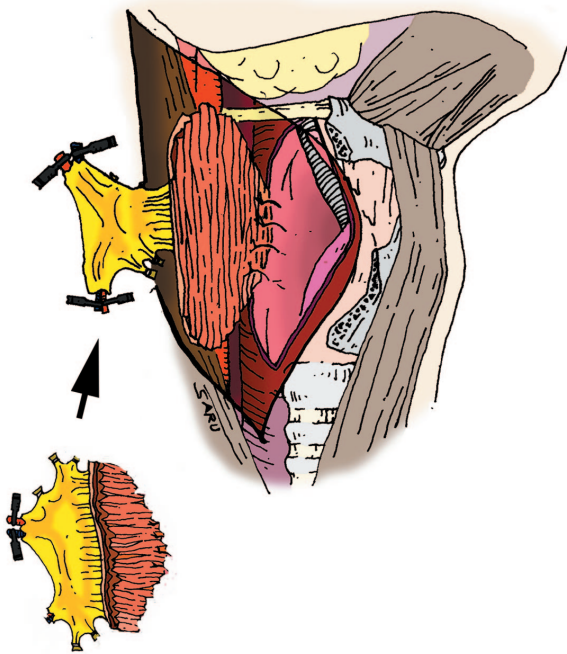


Fig. 1. Illustrations of the conventional method (*below*) and our new procedure (*above*).

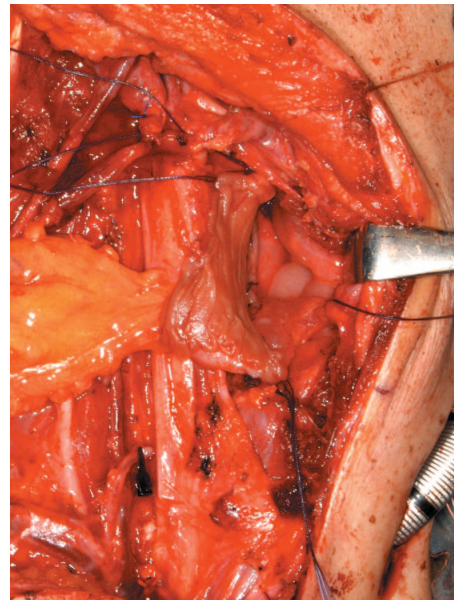


Fig. 2. Intraoperative view of a 64-year-old man with a hypopharyngeal cancer arising on the right pyriform sinus. When the jejunal patch was sutured to the posterior, oral, and anal sides of the hypopharyngeal defect, the mucosal folds extended from the oral to anal sides vertically as the jejunal patch was set in the 90-degree transposed fashion.

laryngeal nerve was cut, although the recurrent nerve was preserved. The validity of our new procedure was assessed compared with our conventional method based on the time required for initiation of oral intake and swallow function (presence of pooling and misswallowing) at the time when the edema of the jejunal flap resolved.

On the first videofluorographic study performed on postoperative day 10, pooling of contrast medium was noted in no patients in the study group and in five of seven patients in the control group. The patients in the study group achieved oral intake 6 days earlier on average than patients in the control group. As a result, all six patients in the study group achieved adequate oral intake, with rare dysphagia or regurgitation (Fig. 3), whereas in the control group, five of seven patients had dysphagia or regurgitation to some extent.

Reconstruction with the radial forearm flap has the advantage of not requiring celiotomy; however, it leaves an ugly scar on the forearm. Furthermore, patients who have undergone reconstruction with the forearm flap often complain of swallowing difficulties and often need the aid of liquids to swallow foods smoothly.¹ The jejunal patch graft, in contrast, has the advantages of having a wet mucosal surface with early wound healing and less scar contracture, allowing the remaining pharynx to move physiologically during swallowing. Although our new procedure is merely a directional alteration of the graft, a disadvantage of the conventional jejunal patch graft can be overcome. In the study group, miswallowing was noted in two patients on the first

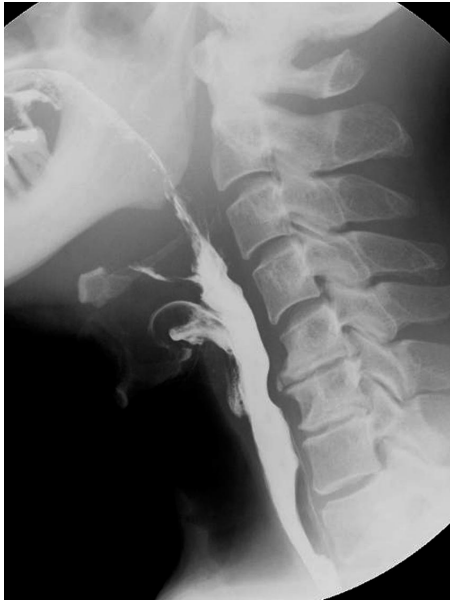

Fig. 3. Videofluorographic study performed 3 months postoperatively shows smooth passage without miswallowing or pooling of contrast medium (same patient as shown in Fig. 2).

videofluorographic study and was probably caused by swelling of the jejunal graft (confirmed by the endoscopic study). However, in our experience, miswallowing can be overcome when the flap edema has resolved, although pooling of food persists. Regarding early-stage hypopharyngeal cancer, radiotherapy is effective for preservation of speech and swallowing function.⁴ However, partial hypopharyngectomy with preservation of the larynx is one of the options for localized cancer.^{1-3,5} We believe that our procedure is one of the suitable options for reconstruction of noncircumferential hypopharyngeal defects following the partial pharyngectomy, provided the patient's general condition permits celiotomy.

DOI: 10.1097/PRS.0b013e318186ca8a

Mutsumi Okazaki, M.D.

Department of Plastic and Reconstructive Surgery
Kyorin University
Tokyo, Japan

Hirohata Asato, M.D.

Department of Plastic and Reconstructive Surgery
Dokkyo University School of Medicine
Tochigi, Japan

Shunji Sarukawa, M.D.

Division of Plastic and Reconstructive Surgery
Jichi Medical School
Tochigi, Japan

Masayuki Okochi, M.D.

Hirohata Suga, M.D.
Department of Plastic and Reconstructive Surgery
Graduate School of Medicine
University of Tokyo
Tokyo, Japan

Correspondence to Dr. Okazaki
Department of Plastic and Reconstructive Surgery
Kyorin University
6-20-2 Shinkawa
Mitaka-City
Tokyo, Japan 181-8611
okazaki-m@umin.ac.jp

Presented at the 30th Annual Meeting of Japan Society for Head and Neck Cancer, in Osaka, Japan, July 14 through 16, 2006.

REFERENCES

1. Nakatsuka, T., Harii, K., Ueda, K., et al. Preservation of the larynx after resection of a carcinoma of the posterior wall of the hypopharynx: Versatility of a free flap patch graft. *Head Neck* 19: 137, 1997.
2. Disa, J. J., Pusic, A. L., Hidalgo, D. A., and Cordeiro, P. G. Microvascular reconstruction of the hypopharynx: Defect classification, treatment algorithm, and functional outcome based on 165 consecutive cases. *Plast. Reconstr. Surg.* 111: 652, 2003.
3. Schwager, K., Hoppe, F., Hagen, R., and Brunner, F. X. Free-flap reconstruction for laryngeal preservation after partial laryngectomy in patients with extended tumors of the oropharynx and hypopharynx. *Eur. Arch. Otorhinolaryngol.* 256: 280, 1999.
4. Lefebvre, J. L., Chevalier, D., Lubinski, B., Kirkpatrick, A., Collette, L., and Sahmoud, T. Larynx preservation in pyriform sinus cancer: Preliminary results of a European Organization for Research and Treatment of Cancer phase III trial. EORTC Head and Neck Cancer Cooperative Group. *J. Natl. Cancer Inst.* 88: 890, 1996.
5. Spiro, R. H., Kelly, J., Vega, A. L., Harrison, L. B., and Strong, E. W. Squamous carcinoma of the posterior pharyngeal wall. *Am. J. Surg.* 160: 420, 1990.

Free Flap Monitoring Using Skin Temperature Strip Indicators: Adjunct to Clinical Examination

Sir:

Free tissue transfer procedures are performed with high levels of success today. Accurate postoperative flap monitoring is critical for favorable surgical outcome. Serial clinical surveillance by an experienced microsurgeon remains the standard of care for free flap monitoring. Unfortunately, this is neither practical nor always possible; therefore, additional medical caregivers are taught this art. In our practice, we have a dedicated hospital wing with experienced nurses monitoring the flaps in the postoperative setting. In most hospital environments, shift-changing nurses, residents, medical students, nurses' aides, and even family members are educated about flap monitoring in an abbreviated manner. Morning rounds can be greeted with unpleasant surprises.

To make free flap monitoring more reliable, various "technological advances" for flap monitoring have been developed to complement clinical evaluation. Technological tools available include laser Doppler imaging, fluorescein blue mapping, lactic acid elevation,

photoplethysmography, differential thermometry, dermo-fluorometry, radioactive microspheres, electromagnetic flowmetry, and internal Doppler devices.¹ Many of these techniques are impractical, unavailable, and expensive.

Surface temperature recordings for flap monitoring have been reported to be successful.^{2,3} Electronic temperature probes are clinically available and require additional leads to be attached to the flap skin island and surrounding skin. Using this cumbersome technique, the patient is soon wrapped in a web of electrocardiographic and temperature probe leads. A simpler solution is the use of anesthesia skin temperature strip indicators (Sharn Anesthesia, Inc., Tampa, Fla.), which can be placed on both the patient's flap skin island and native skin without much trouble (Fig. 1). These temperature strips detect temperature changes of 2°C. Medical personnel can use this additional flap monitoring method along with clinical and Doppler examination. Our experience using temperature strips to monitor perforator flaps is similar to that in the 1979 report by Baudet et al. using infrared thermograms to monitor groin (known today as superficial inferior epigastric artery) free flaps.⁴ It is common to observe a 2°C to 3°C difference between flap and control temperatures in the early postoperative setting. However, an acute drop of 3°C at the center of the skin island is indicative of arterial thrombosis, whereas a 1°C to 2°C uniform drop over of the flap is indicative of venous compromise. Temperature strips can detect these changes with effectiveness equal to that of electronic temperature monitoring.

This adjunctive technique is simple and inexpensive (\$1 per strip). We advocate that this technique complement but *not* replace traditional clinical and handheld Doppler examination. Despite 30 years of greater flap physiology understanding, flap monitoring continues to require competent human clinical judgment.

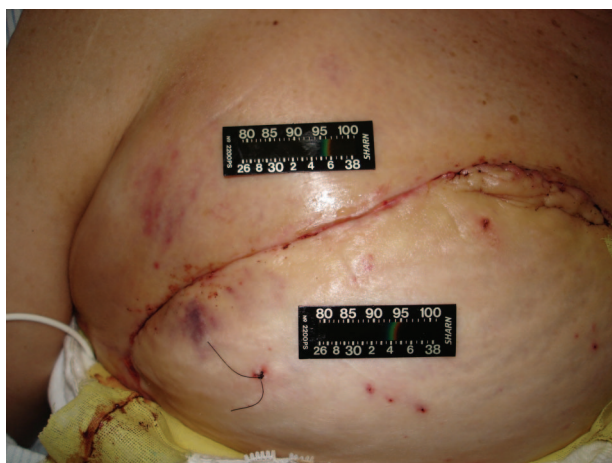

Fig. 1. Temperature strip monitoring after deep inferior epigastric perforator microvascular breast reconstruction.

Improved flap monitoring education for all medical personnel makes for restful evenings.

DOI: 10.1097/PRS.0b013e318186caf3

Ernest S. Chiu, M.D.

Andrew Altman, M.D.

Tulane Health Sciences Center
New Orleans, La.

Robert J. Allen, Jr., B.S.

Robert J. Allen, Sr., M.D.

Center for Microsurgical Breast Reconstruction
Charleston, S.C.

Correspondence to Dr. Chiu

Tulane Health Sciences Center
1430 Tulane Avenue, SL-22
New Orleans, La. 70112
eschiu@tulane.edu

REFERENCES

1. Daniel, R. K., and Kerrigan, C. L. Principles and physiology of skin flap surgery. In J. G. McCarthy (Ed.), *Plastic Surgery*. Philadelphia: Saunders, 1990.
2. Acland, R. D. Experience in monitoring the circulation in free-flap transfers (Discussion). *Plast. Reconstr. Surg.* 68: 554, 1981.
3. Khouri, R. K., and Shaw, W. W. Monitoring of free flaps with surface-temperature recordings: Is it reliable? *Plast. Reconstr. Surg.* 89: 495, 1992.
4. Baudet, J., LeMaire, J.-M., and Buimberteau, J. C. Ten free groin flaps. *Plast. Reconstr. Surg.* 57: 577, 1976.

The Subfascial Perforator Dissection for DIEP Flap Harvest

Sir:

The deep inferior epigastric perforator (DIEP) flap retains a reputation for being a technically demanding flap to raise. Using the traditional technique of DIEP flap harvest, it can be difficult to gain a satisfactory overview of perforator anatomy. This becomes particularly important when there is no “dominant” perforator entering the flap and it is instead nourished by multiple smaller perforators. In this situation, perforator(s) selection becomes more complex and is hampered by an incomplete knowledge of their anatomical interrelationships. In this article, we describe an adjunct for dissecting the DIEP flap that provides superior visualization of the perforators, with attendant benefits for intraoperative safety, speed, and decision-making.

The DIEP flap is elevated from lateral to medial, up to and a little beyond the edge of the anterior rectus sheath. An oblique incision judged to overlie the distal course of the deep inferior epigastric artery is made in the anterior rectus sheath. The cut edges of the sheath are elevated and the underlying rectus abdominis muscle is gently separated from the sheath using blunt dissection. This continues until the anterior rectus sheath is undermined up to and a little beyond any perforating vessels encountered (Fig. 1). In this fash-

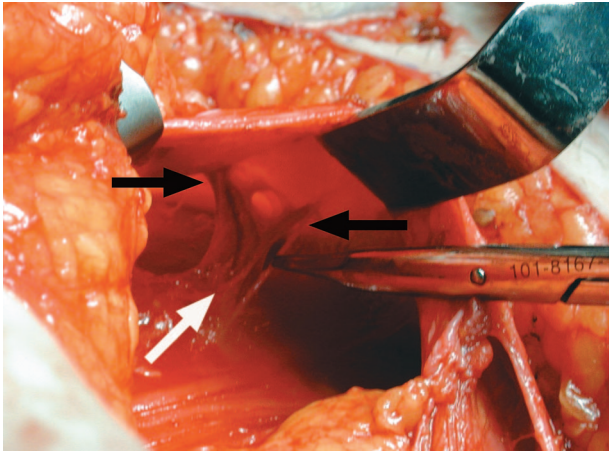


Fig. 1. A cluster of perforating vessels is readily identified and dissected by means of the subfascial approach. Note how the proximal relations (white arrow) of the two perforators (black arrows) are revealed using this approach.

ion, a subfascial “map” of the perforators is developed. This frequently reveals relationships (or lack thereof) between adjacent perforators that are not apparent with the suprafascial dissection alone.

The suprafascial component of the dissection then resumes, expedited by knowledge of the likely exit points of the perforators through the anterior rectus sheath. The initial incision in the rectus sheath is then extended toward the selected perforator(s). After the selected perforator(s) has been isolated and the suprafascial dissection completed, the intramuscular course of the perforator(s) is dissected back to the deep inferior epigastric vessels using standard techniques.

Despite the use of Doppler imaging or duplex ultrasound for preoperative assessment, perforator(s) selection during DIEP flap harvest still necessitates scrupulous intraoperative appraisal in most cases. In selecting a suitable perforator(s), the surgeon must consider factors such as caliber, its location within the flap, and its anatomical relations with adjacent perforators. In appraising these factors, the subfascial dissection technique offers some distinct advantages.

The subfascial plane provides excellent exposure, allowing the surgeon to rapidly appraise the above factors. In particular, it provides superlative information about the course and interrelationships of the individual perforators. This information consistently enhances the decision-making process, leading to a net reduction in operative time despite the extra dissection required. The subfascial dissection also contributes to the safety of the dissection, allowing identification of perforators traveling between the layers of the anterior rectus sheath (intrasheath course) or those following a subfascial course that would ordinarily be at risk of injury during dissection from above (Fig. 2). We have found subfascial dissection to be a very useful adjunct

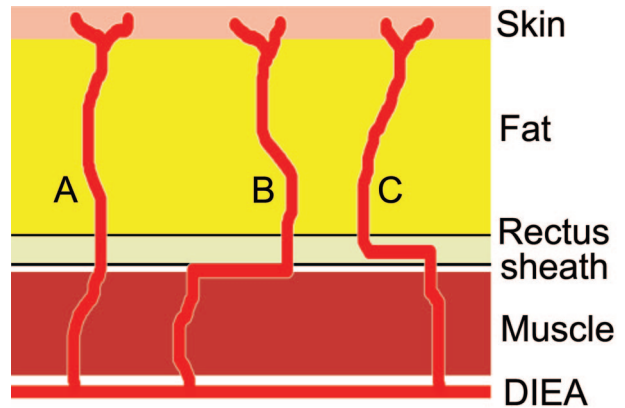


Fig. 2. Diagram illustrating some of the possible relationships between a perforator and the anterior rectus sheath. A, Perforator taking a direct route through the sheath; B, perforator following a subfascial route before piecing the sheath; C, perforator following an intrafascial course. The risk of injury to perforator types B and C is reduced using the subfascial dissection technique. DIEA, deep inferior epigastric artery.

when harvesting the DIEP flap and thoroughly endorse its use.

DOI: 10.1097/PRS.0b013e318186cab6

Ashley Tregaskiss, M.R.C.S.

Alvero Perez-Temprano, M.D.

Robert J. Morris, M.D.

Department of Plastic and Reconstructive Surgery
Derriford Hospital
Plymouth, United Kingdom

Correspondence to Dr. Tregaskiss
Department of Plastic and Reconstructive Surgery
Derriford Hospital
Plymouth PL6, United Kingdom
drtregs@hotmail.com

Superior Gluteal Artery Perforator Flap Based on Septal Perforators: Preliminary Study

Sir:

The superior gluteal artery perforator flap is known as a local flap when used for large defects in the lumbosacral region and as free flap when used for breast reconstruction.¹ Conventionally, its perforators are dissected through the gluteus maximus muscle. In anatomical studies concerning the superior gluteal artery and perforators of the gluteal region, no distinction has been made between septal and musculocutaneous perforators.^{2,3}

Cormack and Lamberty⁴ have described a superficial branch of the superior gluteal artery subdividing between the gluteus maximus and medius muscle into three branches: a posterior branch, an intermediate branch, and an anterior branch. Terminal branches from the anterior branch may emerge at the superolateral edge of the gluteus maximus muscle to pierce

the deep fascia and supply the cutaneous and subcutaneous tissue. We focused our attention on these septal perforators running between the gluteus maximus and the medius muscles.

Formalin-fixed cadavers of three adults were used to study the anatomy in six gluteal regions. In addition, color Doppler analysis was performed in 20 gluteal regions of 10 adult volunteers with a MyLab 25 color Doppler with an LA523, 4- to 13-MHz probe (Esaote, Genova, Italy).

For the anatomical study, in every corpse, at least one septal perforator passing between the gluteus maximus

muscle and the medius muscle was found (range, zero to two for the left side and one to four for the right side). All perforators originated from the anterior branch of the superficial branch of the superior gluteal artery (Table 1).

For the color Doppler study, in every volunteer, at least one septal perforator passing between the gluteus maximus muscle and the medius muscle was found (range, one to three for the left side and zero to four for the right side) (Table 1 and Fig. 1).

In both studies, the projections on the skin of the distance of every perforator from the midsagittal line (Fig. 2) and from a line perpendicular to it at the cranial end of the natal cleft were registered.

The 2003 Gent consensus on perforator flaps clarifies the definition of perforator flaps and underlines

Table 1. Projection of the Distance of Septal Perforators from Line A and Line B on the Skin in Three Corpses and 10 Volunteers

	Side	Distance from Line A	Distance from Line B
Cadaver			
1	Right	8.7	4.8
1	Right	6.0	4.2
1	Right	10.5	3.2
1	Right	14.2	1.0
1	Left	10.8	4.2
1	Left	14.5	1.2
2	Right	9.5	7.0
2	Right	15.2	0.0
2	Left	13.5	2.2
3	Right	14.8	4.2
3	Left		
Volunteer			
1	Left	15	1
1	Left	10	3.5
1	Left	6	6.5
1	Right	15	1.5
1	Right	10.5	3
1	Right	8	4.5
1	Right	5	7
2	Left	14	4
2	Left	18	4
2	Left	8	6.5
2	Right	12	1
2	Right	7	2
2	Right	2.5	3
3	Left	15	3
3	Left	6	5
3	Left	11	5.3
3	Right	14	3
3	Right	5	5
3	Right	9	6
4	Left	15	4
4	Right	9	7
5	Left	15.5	2.5
5	Left	6.5	4
5	Right	14	3.5
5	Right	4	4.5
6	Left	10	5
6	Right	—	—
7	Left	6	5
7	Right	4	3
8	Left	10	7
8	Right	7	6
9	Left	19	2
9	Right	8	5
10	Left	12.5	3.5
10	Right	15	3

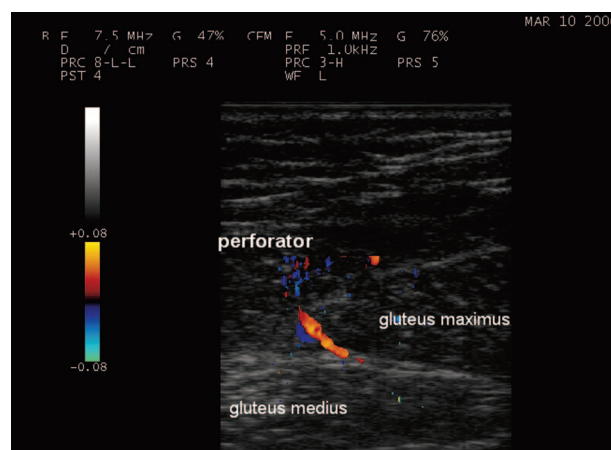


Fig. 1. Color Doppler imaging of a septal perforator in a volunteer.

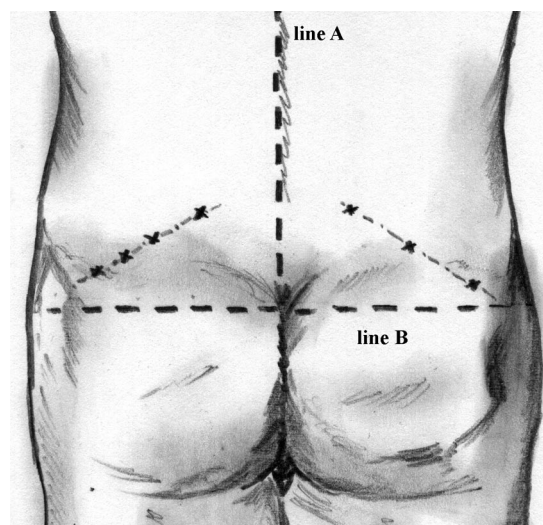


Fig. 2. Projection of the measured positions of the septal perforators on the skin in an average gluteal region giving an impression of their distribution.

that septal perforators are easier to identify and dissect. Consequently, septal perforators, as described above, could make the superior gluteal artery perforator flap technically easier.⁵ In addition, laterally orientated septal perforators improve the arc of rotation in pedicled flaps and provide a long pedicle in free flaps.

We advise preoperatively a color Doppler analysis to identify septal perforators. To include septal perforators, the drawing of the superior gluteal artery perforator flap should be a little higher than conventionally, above line B in Figure 2.

DOI: 10.1097/PRS.0b013e318186caca

Stefania Tuinder, M.D.

René Van Der Hulst, M.D., Ph.D.

Department of Plastic and Reconstructive Surgery
University Hospital Maastricht

Arno Lataster, M.Sc.

Department of Anatomy and Embryology
Maastricht University

Willy Boeckx, M.D., Ph.D.

Department of Plastic and Reconstructive Surgery
University Hospital Maastricht
Maastricht, The Netherlands

Correspondence to Dr. Tuinder
Department of Plastic and Reconstructive Surgery
University Hospital Maastricht
Haspengouw 5A
Maastricht 6227RL, The Netherlands
nervofaciale@yahoo.it

REFERENCES

- Guerra, A. B., Soueid, N., Metzinger, S. E., et al. Simultaneous bilateral breast reconstruction with superior gluteal artery perforator (SGAP) flap. *Ann. Plast. Surg.* 53: 305, 2004.
- Kankaya, Y., Ulusoy, M. G., Oruc, M., Yildiz, K., Kocer, U., and Tuccar, E. Perforating arteries of the gluteal region: Anatomic study. *Ann. Plast. Surg.* 56: 409, 2006.
- Koshima, I., Moriguchi, T., Soeda, A., Kawata, S., Ohta, S., and Ikeda, A. The gluteal perforator-based flap for repair of sacral pressure sores. *Plast. Reconstr. Surg.* 91: 678, 1993.
- Cormack, G. C., and Lamberty, B. G. H. *The Arterial Anatomy of Skin Flaps*, 2nd Ed. New York: Churchill Livingstone, 1994. Pp. 218–222.
- Blondeel, P. N., Van Landuyt, K. H., Monstrey, S. J., et al. The “Gent” consensus on perforator flap terminology: Preliminary definitions. *Plast. Reconstr. Surg.* 112: 1378, 2003.

A Survey of Attitudes of Ontario Plastic Surgeons Leading up to the Return of Silicone Implants

Sir:

The government of Canada introduced round silicone gel implants to the Canadian market through the Special Access Program in 1999. Anatomical silicone gel implants became available through the Special Access Program in 2000. There has been a large increase in the use of silicone implants by Canadian plastic surgeons since the Special Access Program reintro-

duced them into the Canadian market in 2000. This increase is consistent across all provinces in Canada. The most dramatic increase in use has been for breast augmentation (Fig. 1).

Health Canada lifted the restricted use label in October of 2006, granting licenses to Allergan, Inc. (Irvine, Calif.) and Mentor Medical Systems (Santa Barbara, Calif.) to market their silicone gel implants in Canada.¹ The U.S. Food and Drug Administration quickly followed suit in November of 2006, also approving the marketing of silicone gel implants made by Allergan and Mentor for breast reconstruction and augmentation.²

A survey tailored to practicing plastic surgeons in Ontario was designed to evaluate surgeons' attitudes toward the use of silicone implants for breast reconstruction and augmentation procedures.

There was a 64 percent (89 of 140) response rate to the survey. Although silicone implants were the most common preference for reconstruction patients (46 percent), saline implants (21 percent) and autologous tissue (30 percent) were also commonly indicated as preferences. Surgeon preferences were more evenly divided for their augmentation patients, as 45 percent preferred silicone implants, 45 percent preferred saline implants, and 10 percent indicated they made their choice based on the patient's preference. Many surgeons felt that shape (54 percent), consistency (78 percent), and durability (41 percent) were benefits of silicone implants. Few surgeons (<3 percent) rated these qualities as advantages of saline implants. However, 75 percent of surgeons listed other advantages of saline implants, including a smaller incision for insertion, less patient anxiety, and less expense for the patient.

Surgeons were asked to consider the following earlier controversies surrounding silicone implants:

1. Increased cancer risk
2. Increased risk of connective tissue diseases
3. Increased incidence of fibromyalgia
4. Existence of systemic silicone syndrome

The majority of surgeons currently feel that all of these issues are likely either false or will be proven to be false.

Surgeons were then asked how much these issues currently influence their decision to recommend silicone implants to either reconstruction or augmentation patients. With regard to the reconstruction patients, 38 percent feel these issues do not at all influence their decision to recommend silicone implants. However, 17 percent feel these issues affect their decision to recommend silicone implants greatly, and 33 percent feel they affect their decision moderately. With regard to augmentation patients, 36 percent feel these issues do not at all influence their decision to recommend silicone implants. However, 20 percent feel these issues affect their decision to recommend silicone implants greatly, and 39 percent feel they affect their decision moderately.

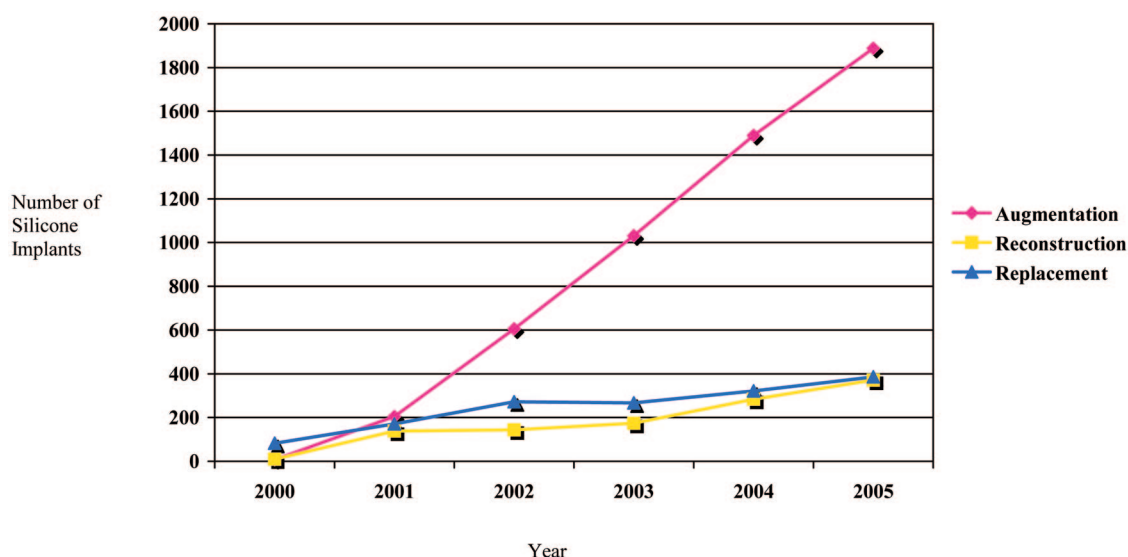


Fig. 1. Silicone implant use in Ontario from 2000 to 2005 according to type of surgery.

Leading up to the release of silicone breast implants in Canada, plastic surgeons in Ontario had been using increasing numbers of silicone implants. This seems to reflect increased confidence in the safety of silicone implants. Many plastic surgeons feel that silicone implants have advantages over saline implants, including shape, consistency, and durability, which also may in part account for the resurgence of silicone implant use.

We recognize that since Health Canada and the U.S. Food and Drug Administration have made silicone implants more accessible, some of the concerns noted in our survey may no longer be present.

DOI: 10.1097/PRS.0b013e3181882436

Laura Snell, M.D.

Nancy Baxter, M.D.

John L. Semple, M.D.

Sunnybrook Women's College Health Center
Toronto, Ontario, Canada

Correspondence to Dr. Semple
Sunnybrook Women's College Health Center
2075 Bayview Avenue
Toronto, Ontario M4N 3M5, Canada
john.semple@wchospital.ca

DISCLOSURE

None of the authors has a financial interest in any of the products, devices, or drugs mentioned or implied in this article.

REFERENCES

1. Health Canada, Health Products and Food Branch, Ottawa, Ontario, Canada. Available at: <http://www.hc-sc.gc.ca>. Accessed July 10, 2008.
2. Health Canada News. Health Canada grants manufacturers Class IV licenses with conditions to market silicone gel-filled implants. Available at: <http://www.hc-sc.gc.ca>. Accessed July 10, 2008.

End-to-Side Anastomosis to the Internal Mammary Artery in Free Flap Breast Reconstruction: Preserving the Internal Mammary Artery for Coronary Artery Bypass Grafting

Sir:

Myocardial revascularization has become an indispensable tool in the management of ischemic heart disease over the past four decades. Because of its long-term patency as compared with venous grafts,^{1,2} the left internal mammary artery-to-left anterior descending artery graft has been the standard of care in bypass surgery since the mid-1980s.³ In addition, the internal mammary artery's location, patency, and favorable diameter have also led to its routine use by plastic surgeons.^{1,4}

Unfortunately, when the internal mammary arteries are used as the recipient vessels in microvascular breast reconstruction and anastomosed in an end-to-end fashion, they are rendered too short to reach the coronary artery, making them unavailable for future myocardial revascularization. This loss of the internal mammary artery as a potential conduit for myocardial revascularization could adversely affect some patients should they develop coronary artery disease requiring coronary artery bypass grafting. Fortunately, by anastomosing the flap's vascular pedicle to its internal mammary recipient vessels in an end-to-side fashion, we can preserve the internal mammary artery in its distal course for future myocardial revascularization.

We have performed five deep inferior epigastric perforator flap reconstructions to date using an end-to-side arterial anastomosis. All five patients have recovered without significant morbidity (Fig. 1). Our recommended surgical technique is as follows. Exposure of the internal mammary vessels is made by excising the cartilaginous portion of the third rib to create a win-

dow. We then perform the typical end-to-end venovenous anastomosis between the internal mammary vein and inferior epigastric vein with a venous coupler device or 8-0 nylon. For arterial anastomosis, a double approximating microvascular clamp for proximal and distal control of the internal mammary artery is used. Next, a circular arteriotomy with the Banis ASSI arteriotomy forceps allows for an end-to-side anastomosis between the inferior epigastric artery and the internal mammary artery by means of an interrupted 8-0 nylon suture (Fig. 2).

We know that the sternum and internal mammary artery have an extensive collateral blood supply.⁵ In addition, experience has shown that cutaneous perforator flaps develop rich collateral blood supplies that sustain them after their vascular pedicles are disrupted in the setting of debulking and recontouring. Considering this, should the need arise for coronary artery revascularization in one of our patients, the deep inferior epigastric pedicle can be safely divided without compromising the viability of the reconstructed breast (deep inferior epigastric perforator flap).

It is entirely foreseeable that patients who have undergone the standard end-to-end anastomosis in free flap breast reconstructions may require future coronary artery revascularizations. In that event, heart surgeons and patients will face an unpleasant realization that the use of their internal mammary artery as a conduit is no longer a possibility. Because of this, the preservation of the internal mammary artery as a bypass conduit in the manner described is an option that should be widely considered in the context of free flap breast reconstruction. Admittedly, our patient population reflects the infancy of this new approach, but we will continue

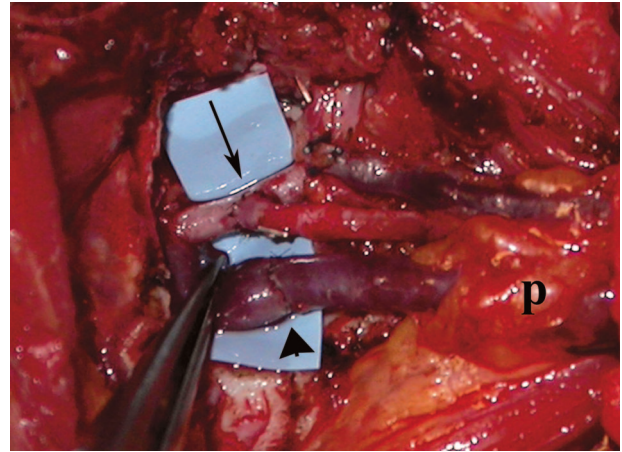


Fig. 2. End-to-side arterial anastomosis (arrow) and end-to-end venovenous anastomosis (arrowhead) of pedicle (p) to internal mammary vessels.

to use this method of vascularization with the intention of comparing our long-term results with those of the traditional end-to-end anastomoses. We would also like to explore the outcomes of myocardial revascularization using the internal mammary arteries of these patients.

DOI: 10.1097/PRS.0b013e318186cb06

Amani F. Hemphill, M.D.

Ramon A. de Jesus, M.D.

Nathaniel McElhaney, M.D.

Jonathan P. Ferrari, B.S.

Department of Surgery
Union Memorial Hospital
Baltimore, Md.

Correspondence to Dr. de Jesus
Department of Surgery
Union Memorial Hospital
200 East 33rd Street, Suite 429
Baltimore, Md. 21208
toe_2_hand@yahoo.com

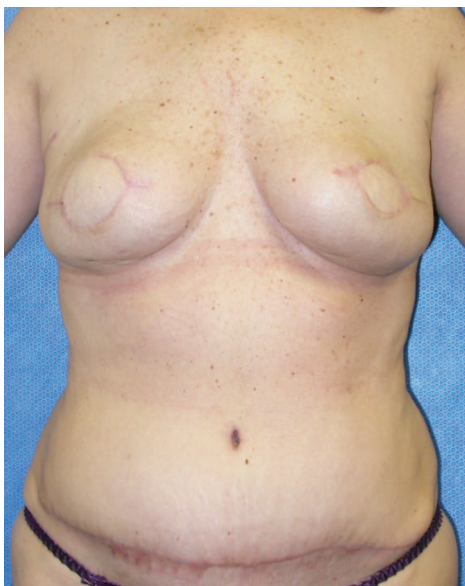

Fig. 1. View of a patient at 10 weeks after bilateral deep inferior epigastric perforator flap breast reconstruction.

REFERENCES

1. Nahabedian, M. Y. The internal mammary artery and vein as recipient vessels for microvascular breast reconstruction. *Ann. Plast. Surg.* 53: 311, 2004.
2. Loop, F. D. Internal-thoracic artery grafts: Biologically better coronary arteries. *N. Engl. J. Med.* 334: 216, 1996.
3. Loop, F. D., Lyte, B. W., Cosgrove, D. M., et al. Influence of the internal-mammary artery graft on 10 year survival and other cardiac events. *N. Engl. J. Med.* 314: 1, 1986.
4. Dupin, C. L., Allen, R. J., Glass, C. A., and Bunch, R. The internal mammary artery and vein as recipient site for free-flap breast reconstruction: A report of 110 consecutive cases. *Plast. Reconstr. Surg.* 98: 685, 1996.
5. de Jesus, R. A., and Acland, R. D. Anatomic study of the collateral blood supply of the sternum. *Ann. Thorac. Surg.* 59: 163, 1995.

Necrotizing Fasciitis of the Breast

Sir:

Necrotizing fasciitis of the breast is a rare entity, with only a handful of cases reported in the literature.¹⁻³ The robust blood supply of the breast makes salvage possible if this condition is recognized early.

A 38-year-old woman with no comorbidities presented with a 1-week history of left breast pain, swelling, and fever. She was seen at another hospital and diagnosed with left breast cellulitis. Despite treatment with antimicrobial agents, her symptoms became progressively worse and she was transferred to our care. Figure 1 shows her physical findings at admission. Her laboratory parameters were as follows: white blood cell count, 26 cells/mm³; hemoglobin, 10.8 g/dl; sodium, 134 mM; creatinine, 2.1 mg/dl; glucose, 110 mg/dl; and C-reactive protein, 60 mg/liter (Laboratory Risk Indicator for Necrotizing Fasciitis score = 8) (Table 1). Magnetic resonance imaging demonstrated findings consistent with left breast necrotizing fasciitis, which was confirmed at debridement (Fig. 2). The necrotic fascia, nonviable skin, subcutaneous tissue, and small amount of breast parenchyma in the lower outer quadrant were excised. The remaining breast parenchyma was viable and thus preserved. A second look 24 hours later noted the wound to be clean, with no progression of the fasciitis. The wound was subsequently closed by secondary suture.

Necrotizing fasciitis of the breast usually necessitates mastectomy because of delayed diagnosis.¹⁻³ This condition has variously been misdiagnosed as cellulitis, abscess, and even inflammatory breast cancer. The cutaneous features of necrotizing fasciitis as the disease evolves from early to intermediate to late stages have previously been described.⁴ In the breast, however, because of the thicker tissue between the deep fascia and

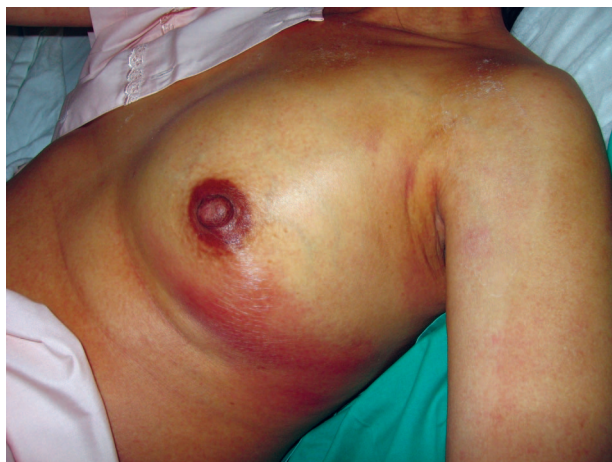

Fig. 1. Her left breast was swollen, warm, erythematous, and tender. Maximal tenderness and skin changes were noted over the lower outer quadrant of the breast.

Table 1. The Laboratory Risk Indicator for Necrotizing Fasciitis Score*

Variable	Points
C-reactive protein	
<150 mg/liter	4
>150 mg/liter	0
White blood cell count	
<15 cells/mm ³	0
15–25 cells/mm ³	1
>25 cells/mm ³	2
Hemoglobin level	
>13.5 g/dl	0
11–13.5 g/dl	1
<11 g/dl	2
Sodium level	
≥135 mM	0
<135 mM	2
Creatinine level	
≤1.6 mg/dl	0
>1.6 mg/dl	2
Glucose level	
≤180 mg/dl	0
>180 mg/dl	1

*The Laboratory Risk Indicator for Necrotizing Fasciitis (LRINEC) score was designed specifically to distinguish necrotizing fasciitis from other soft-tissue infections. This score was developed from a laboratory test commonly performed for the assessment of severe soft-tissue infection and widely available across different institutions. Six independent variables were identified and each gives a specific point toward the final score. The LRINEC score is calculated by summing the points assigned to each of the six variables that make up the score. A score of less than 6, 6 to 7, or 8 or higher is designated as low, intermediate, or high risk, respectively, for the presence of necrotizing fasciitis. We recommend early imaging or operative exploration for suspicious cases with a score of 6 or higher. (Adapted from Wong, C. H., Khin, L. W., Heng, K. S., Tan, K. C., and Low, C. O. The LRINEC (Laboratory Risk Indicator for Necrotizing Fasciitis) score: A tool for distinguishing necrotizing fasciitis from other soft tissue infections. *Crit. Care Med.* 32: 1535, 2004.)

the skin, cutaneous signs may not be apparent until the disease is well advanced, by which time the breast is not salvageable.

A high index of suspicion is, therefore, of paramount importance. Pain out of proportion to visible skin changes, swelling, and warm skin may be the only presenting complaints. The paucity of specific cutaneous signs early in the course of the disease makes early recognition very difficult in the breast when compared with other areas of the body. Diagnostic adjuncts that can help in early recognition of the disease are particularly helpful in this area of the body and should be an integral part of the assessment of suspicious cases. In this context, the Laboratory Risk Indicator for Necrotizing Fasciitis score is a valuable tool.⁵

Intraoperatively, an incision should be made down the pectoralis muscle over the area of maximal tenderness and most obvious skin involvement. The extent of infection can be delineated by bluntly probing the wound, and any area in which the deep fascia can be lifted off the underlying muscle is involved. The deep fascia must be excised completely. The skin, subcutaneous tissue, and breast parenchyma are progressively

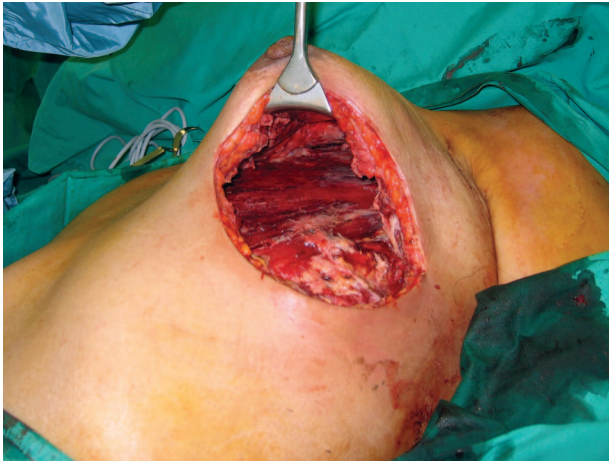


Fig. 2. A wide incision was made over the area of maximal tenderness. Necrotizing fasciitis was confirmed with necrotic fascia and copious "dishwater" pus. The involved fascia extended from the second rib to the sixth rib and from the sternal border to the anterior axillary fold. The necrotic fascia, nonviable skin, and subcutaneous tissue were excised completely. The pectoralis muscle was healthy and the overlying breast parenchyma was viable and therefore preserved.

cut back sharply from the edges of the incision and from the deep aspect of the wound until healthy, uninfected tissue with good bleeding is encountered. The aim of surgery must be to completely remove all infected tissue at the first debridement.

DOI: 10.1097/PRS.0b013e318186cd92

Chin-Ho Wong, M.R.C.S.

Bien-Keem Tan, F.R.C.S.

Department of Plastic, Reconstructive, and
Aesthetic Surgery
Singapore General Hospital
Singapore

Correspondence to Dr. Wong
Department of Plastic, Reconstructive, and
Aesthetic Surgery
Singapore General Hospital
Outram Road
Singapore 169608
wchinho@hotmail.com

DISCLOSURE

The authors did not receive any funding for this work and declare that they have no conflict of interest regarding this article.

REFERENCES

1. Rajakannu, M., Kate, V., and Ananthakrishnan, N. Necrotizing infection of the breast mimicking carcinoma. *Breast J.* 12: 266, 2006.
2. Nizami, S., Mohiuddin, K., Mohsin-e-Azam, Zafar, H., and Memon, M. A. Necrotizing fasciitis of the breast. *Breast J.* 12: 168, 2006.

3. Shah, J., Sharma, A. K., O'Donoghue, J. M., Mearns, B., Johri, A., and Thomas, V. Necrotizing fasciitis of the breast. *Br. J. Plast. Surg.* 54: 67, 2001.
4. Wong, C. H., and Wang, Y. S. The diagnosis of necrotizing fasciitis. *Curr. Opin. Infect. Dis.* 18: 101, 2005.
5. Wong, C. H., Khin, L. W., Heng, K. S., Tan, K. C., and Low, C. O. The LRINEC (Laboratory Risk Indicator for Necrotizing Fasciitis) score: A tool for distinguishing necrotizing fasciitis from other soft tissue infections. *Crit. Care Med.* 32: 1535, 2004.

W-Shaped Mammary Gland Resection for Reduction Mammoplasty

Sir:

We reported the dermal bra technique for reduction mammoplasty and correction of ptosis in 2003.¹ The W-shaped mammary gland resection technique has been applied clinically as a modification of this technique since 2001, based on the following anatomical features: the blood supply of the inferior gland is more sufficient than the superior gland,² and the anterior and lateral branches of intercostal nerves run anteroinferiorly.

A W-shaped glandular resection was performed on the upper part of the breast. The starting point was located on the sternum edge of the fourth intercostal space. The cutting line ran inferolaterally, reversed superiorly at the level of the nipple, and then ran along the edge of the dermal bra. The lateral lowest point was at the level of the nipple. The endpoint was at the intersection of the anterior axillary line and the fourth intercostal space. In very large breasts, the medial lowest point might shift inferiorly, and care should be taken to avoid injuring the deep branches of the lateral subcutaneous branches of the fourth intercostal nerve. After resection of the gland was finished, the remaining gland presented three peaks (A, B, and C glandular flaps from medial to lateral).

The B and C flaps were rotated medially. The B flap was sutured to the A flap, and the C flap was sutured to B. Thus, the base of the breast was reduced and a projective breast mound was created. If the dermal bra was not sufficient to cover the remaining gland, a knitted polypropylene mesh could be used as a substitute for the dermal bra as described by Goes.

We studied 38 patients (76 breasts) ranging in age from 16 to 55 years, whose preoperative breast volume ranged from 686 to 1820 mm³ and whose weight of the gland excised ranged from 348 to 1475 g. The short-term complications included postponed wound healing in three breasts, fat necrosis in two breasts, subcutaneous fluid accumulation in two breasts, and no response to pressure of the nipple-areola and no sensitivity to touch in one breast.

Twenty-seven patients were followed up from 6 to 24 months, and 25 patients acquired satisfactory appearance. Only one patient presented a slightly wider scar around the areola and mild asymmetry. The secondary treatment was performed 1 year later and a satisfactory result was acquired. One patient who had immediately

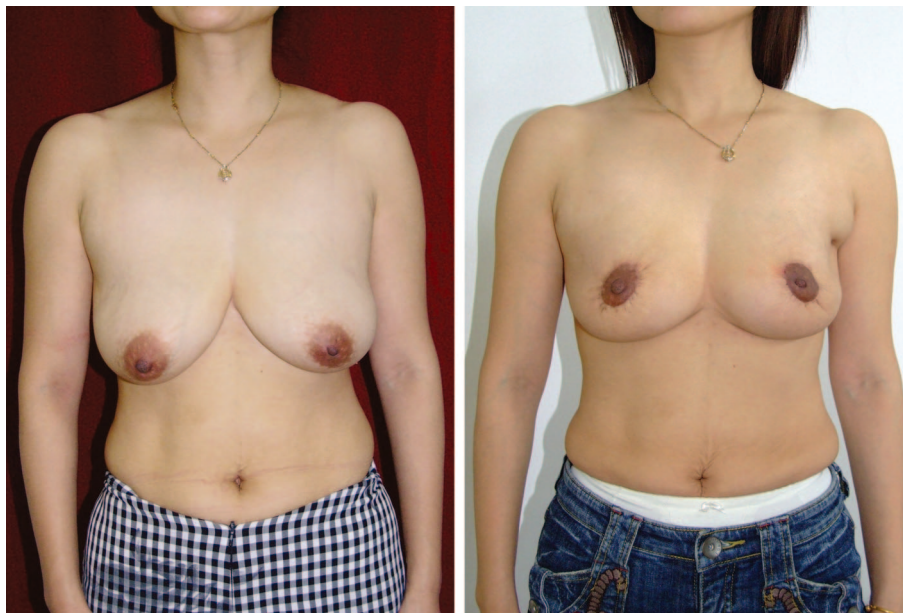


Fig. 1. Preoperative (left) and 1-month postoperative (right) views of a woman who underwent W-shaped mammary gland resection reduction mammoplasty.

sensed a decrease of nipple-areola sensation postoperatively complained of a permanent loss of the sensation of the right nipple-areola (Fig. 1).

The modifications in this technique include the following. The B and C flaps were revolved medially and superiorly, diminished the mammary base, increased the degree of mammary protrusion, and avoided the result of flat breast. The medial part of the W shape could extend inferiorly to increase the amount of removed mammary tissue without injuring the lateral cutaneous branch. Mammoplasty was not completely dependent on the dermal bra; it was performed before fixation of the dermal bra, diminishing the possibility of secondary ptosis.

To avoid injuring lateral cutaneous branches of the fourth intercostal nerve, resection of the lateral group of the glandular tissue should not surpass the 4-o'clock position for the left breast and the 8-o'clock position for the right breast.

DOI: 10.1097/PRS.0b013e31818823b1

Jiaming Sun, M.D.

Ke Guo

Weiwei Li, M.D.

Plastic Surgery Division
Wuhan Union Hospital

Affiliated with Tongji Medical College
Huazhong University of Science and Technology
Wuhan

Qun Qiao, M.D.

Plastic Surgery Division
Beijing Union Hospital

Affiliated with China Union Medical University
Beijing, China

Correspondence to Dr. Sun
Plastic Surgery Division
Wuhan Union Hospital

Affiliated to Tongji Medical College
Huazhong University of Science and Technology
Wuhan, China 430022

DISCLOSURE

None of the authors has a financial interest in anything related to the publication of this article.

REFERENCES

1. Qiao, Q., Sun, J., Liu, C., Liu, Z., and Zhao, R. Reduction mammoplasty and correction of ptosis: Dermal bra technique. *Plast. Reconstr. Surg.* 111: 1122, 2003.
2. Vilain, R. Modification of the Biesenverger procedure. In R. M. Goldwyn (Ed.), *Plastic and Reconstructive Surgery of the Breast*. Boston: Little, Brown, 1976. Pp. 155–164.

Necessity of Vitamin B₁₂ Replacement following Free Ileocolon Flap Transfer

Sir:

Free ileocolon flaps have recently been described for the reconstruction of swallowing and voice function after pharyngolaryngectomy.¹ Although good functional results have been reported, donor-site morbidity still represents a major concern. Physiologically, the ileum is responsible for the assimilation of a substantial portion of the fluids and secretions coming from the jejunum. Vitamin B₁₂ and bile acids are electively assimilated at this level through site-specific receptors. The ileum tends to have shorter villi and reduced surface area when compared with the jejunum; however,

if partially resected, it is capable of massive adaptation by increasing its surface area.^{2,3} Many studies have been performed to clarify maximal ileal resection lengths without incurring malabsorption,⁴ but most of these studies are in patients affected by Crohn's disease. In this group, an ileal resection of more than 60 cm invariably resulted in decreased vitamin B₁₂ absorption, and even resections of 10 cm or less were associated with malabsorption in 38 percent of patients.⁵

In the past, we have always prescribed dietary integration with oral vitamin B₁₂ after free transfer with ileocolon flaps. Given the reduced compliance of patients taking long-term medications and the associated cost, we decided to investigate blood vitamin B₁₂ levels in patients who underwent head and neck reconstruction with free ileocolon flaps.

Seventeen patients were followed up for an average period of 15 months. The transferred ileum segment ranged between 15 and 30 cm. Blood samples were taken at 6-month intervals for 1.5 years and then every year for 2 years. All of the patients who were taking oral integration (12 patients) exhibited vitamin B₁₂ levels at the higher limit or over the normal range values, whereas the patients ($n = 5$) who had abandoned the medication showed values within the normal range (211 to 911 pg/ml) (Fig. 1). We compared the results of the blood tests at different stages during the follow-up, but we did not find a statistically significant difference using the *t* test.

We conclude that resection of up to 30 cm of the terminal ileum (from the ileocecal valve proximally) does not compromise vitamin B₁₂ absorption in a normal patient population. Free ileocolon flaps may be raised safely using up to 30 cm of terminal ileum without requiring supplemental oral vitamin B₁₂.

DOI: 10.1097/PRS.0b013e318186cda7

Antonio Rampazzo, M.D.
Christopher J. Salgado, M.D.

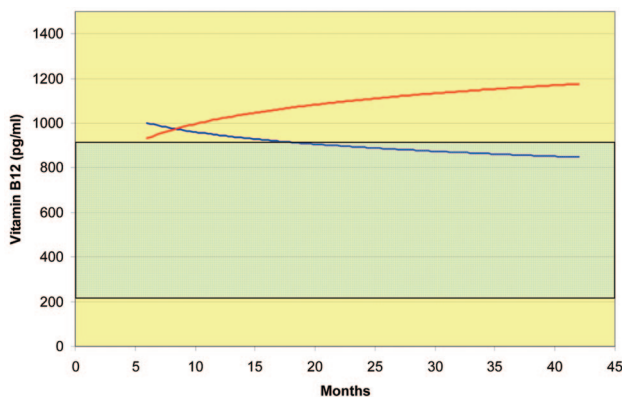


Fig. 1. Vitamin B₁₂ levels after free ileocolon transfer. The light green area represents the normal range of blood vitamin B₁₂. The red regression line indicates patients taking vitamin B₁₂ oral integration, and the blue regression line is for patients not taking supplementation.

Bahar Bassiri Gharb, M.D.

Tsung-Te Chung, M.D.

Samir Mardini, M.D.

Hung-Chi Chen, M.D.

E-Da Hospital
I-Shou University
Kaohsiung, Taiwan

Correspondence to Dr. Salgado
Department of Plastic Surgery
University Hospitals of Cleveland/Case Western
Reserve University
11100 Euclid Avenue
Cleveland, Ohio 44106

REFERENCES

- Chen, H. C., Mardini, S., and Yang, C. W. Voice reconstruction using the free ileocolon flap versus the pneumatic artificial larynx: A comparison of patients' preference and experience following laryngectomy. *J. Plast. Reconstr. Aesthet. Surg.* 59: 1269, 2006.
- Dowling, R. H., and Booth, C. C. Structural and functional changes following small intestinal resection in the rat. *Clin. Sci.* 32: 139, 1967.
- Hanson, W. R., Osborne, J. W., and Sharp, J. G. Compensation by the residual intestine after intestinal resection in the rat: I. Influence of amount of tissue removed. *Gastroenterology* 72: 692, 1977.
- Filipsson, S., Hultén, L., and Lindstedt, G. Malabsorption of fat and vitamin B12 before and after intestinal resection for Crohn's disease. *Scand. J. Gastroenterol.* 13: 529, 1978.
- Behrend, C., Jeppesen, P. B., and Mortensen, P. B. Vitamin B12 absorption after ileorectal anastomosis for Crohn's disease: Effect of ileal resection and time span after surgery. *Eur. J. Gastroenterol. Hepatol.* 7: 397, 1995.

The Microanastomotic Coupler Masquerading as a Foreign Body

Sir:

Everting ring-pin devices have been touted primarily to allow rapid microanastomoses and have evolved today to become probably the most successful nonsuture technique available. The minimal risk of thrombosis and patency rates may be even better than that of hand-sewn anastomoses.¹ Although iatrogenic injury during fixation of the vessel on the stainless steel pins—such as intimal tearing that can propagate into the lumen and be a cause of thrombosis, or pull-through at a pin site leading to premature dislodging of the vessel from the ring—have been reported,^{1,2} few, if any, other untoward events have been compiled,³ to which the following must be added.

A 14-year-old boy sustained a gunshot wound to his left long finger with destruction of the proximal interphalangeal joint. A left second toe vascularized joint transfer relied on a branch of the greater saphenous vein for venous outflow. This was anastomosed to a dorsal hand vein using a 2.5-mm coupler with the GEM Microvascular Anastomotic Coupler System (Synovis Micro Companies Alliance, Inc., Birmingham, Ala.).

The transfer survived completely, but 1 year later, after edema had resolved, he complained of a firm, mobile, tender nodule near the surgical scar on the dorsum of his hand (Fig. 1). The coupler itself proved to be this prominent foreign body (Fig. 2). Its removal at this late date did not affect the viability of the sentinel skin paddle taken with the toe transfer.

Because the available microanastomotic ring-pin couplers are firm and inelastic structures, placement in superficial locations should be performed cautiously, as they can later become palpable and symptomatic. Although their removal would for the same reasons be relatively easy, this is still another surgical procedure. Perhaps the development of an absorbable device would eliminate even these concerns.⁴

DOI: 10.1097/PRS.0b013e318186cd42

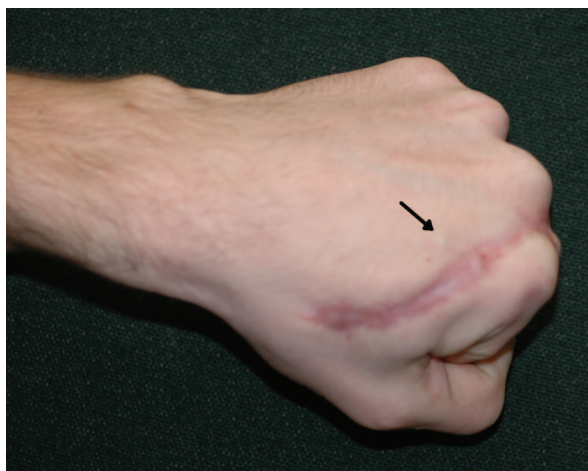

Fig. 1. Firm nodule (arrow) near the surgical scar on the dorsum of the left hand.

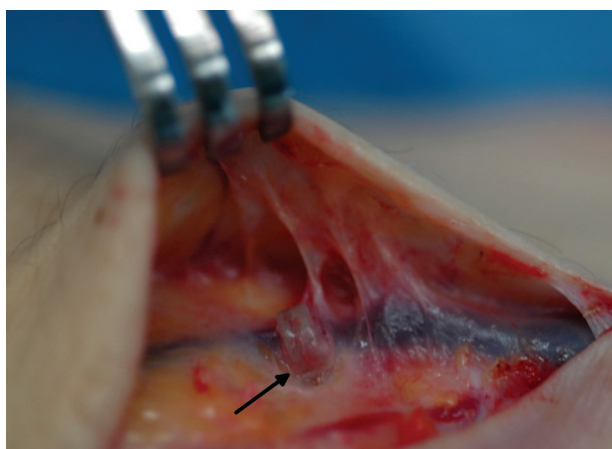


Fig. 2. Reopening the existing scar revealed the foreign body to be the coupler (arrow), with blood-filled and still patent veins seen on either side of the anastomosis.

Geoffrey G. Hallock, M.D.

Division of Plastic Surgery
The Lehigh Valley Hospitals and Sacred Heart Hospital
Allentown, Pa.

Correspondence to Dr. Hallock
1230 South Cedar Crest Boulevard, Suite 306
Allentown, Pa. 18103
pbhallock@cs.com

DISCLOSURE

The author has no financial interests to disclose.

REFERENCES

1. Yap, L. H., Constantinides, J., and Butler, C. E. Venous thrombosis in coupled versus sutured microvascular anastomoses. *Ann. Plast. Surg.* 57: 666, 2006.
2. Ahn, C. Y., Shaw, W. W., Berns, S., and Markowitz, B. L. Clinical experience with the 3M microvascular coupling anastomotic device in 100 free-tissue transfers. *Plast. Reconstr. Surg.* 93: 1481, 1994.
3. Hallock, G. G., and Rice, D. C. On "management of significant venous discrepancy with microvascular venous coupler." *J. Reconstr. Microsurg.* 20: 59, 2004.
4. Daniel, R. K., and Olding, M. An absorbable anastomotic device for microvascular surgery: Experimental studies. *Plast. Reconstr. Surg.* 74: 329, 1984.

Spigelian Herniation after Component Separation

Sir:

A 61-year-old man had an aortic valve replacement in 2003. Postoperatively, he required a gastrectomy for a bleeding gastric ulcer and subsequently required three more open laparotomies that resulted in a large ventral hernia. Repair of this incisional hernia, measuring 12 × 8 cm, had been attempted on two occasions unsuccessfully. At the time of this repair, the general surgeon resected mesh from a previous repair and lysed the adhesions. The reconstructive team then performed a standard bilateral component separation, which was performed successfully, with complete closure of the abdominal wall without the use of mesh. The patient was admitted to the surgical intensive care unit, where he was placed on a ventilator for 4 days while bladder pressures were monitored. On the sixth postoperative day, his hemoglobin and hematocrit levels dropped and he had clearly developed increased abdominal distention. Subjectively, he complained of increased abdominal pain. A computed tomographic scan of the abdomen was obtained and a large Spigelian hernia lateral to the right rectus abdominis muscle was noted.

He was taken back to the operating room emergently. Inspection of the abdominal wall showed that the midline sutures between the rectus muscles were intact and that a Spigelian hernia extended from the rib margin to the level of the pubic symphysis. The defect was closed partially superiorly and inferiorly with 0 Prolene sutures (Ethicon, Inc., Somerville, N.J.). AlloDerm (LifeCell Corp., Branchburg, N.J.) was used

to close the rest of the defect and the entire area was reinforced with Dexon mesh (Syneture, a division of Covidien, Norwalk, Conn.). Tension from the hernia resulted in devascularization of some of the abdominal skin. This was excised and a vacuum-assisted closure device (Kinetic Concepts, Inc., San Antonio, Texas) was applied. The patient was moved to the surgical intensive care unit in stable condition and kept on a ventilator for 8 days. His postoperative course was uneventful and he was discharged home 2 weeks later. The vacuum-assisted closure device was changed two times per week, and the healthy, granulating wound was ultimately skin grafted.

The component separation procedure was first introduced by Ramirez et al., when 11 patients with considerable abdominal wall defects underwent reconstruction by separation of the anatomical components of the abdominal wall.¹ The procedure consists of elevation of the external oblique muscle from the underlying internal oblique, elevation of the rectus abdominis from its posterior sheath, and medial advancement of this muscle complex to close the defect. This method was shown to be superior to the placement of mesh and free fascial or musculofascial flaps and also provided additional support and a more physiologic reconstruction of the abdominal wall. In 1999, Shestak et al. mentioned the possibility of Spigelian herniation with this operation if “dissection is not limited to the external oblique-internal oblique interface.”²

Component separation has been a major improvement in treating difficult incisional hernias. Our case reinforces the real risk of Spigelian hernia when this technique is used. Where significant advances are needed to achieve a successful closure, we would now advocate using AlloDerm or some form of mesh to reinforce the lateral releasing incision, thereby reducing this risk.

DOI: 10.1097/PRS.0b013e318186cd06

Donald R. Mackay, M.D.

Julia C. Stevenson, B.S.

Pennsylvania State University College of Medicine
Milton S. Hershey Medical Center
Hershey, Pa.

Correspondence to Julia Stevenson
232 University Manor East
Hershey, Pa. 17033
jcstevenson@psu.edu

REFERENCES

1. Ramirez, O., Ernesto, R., and Dellon, A. “Component separation” method for closure of abdominal-wall defects: An anatomic and clinical study. *Plast. Reconstr. Surg.* 86: 519, 1990.
2. Shestak, K., Edington, H., and Johnson, R. The separation of anatomic components technique for the reconstruction of massive midline abdominal wall defects: Anatomy, surgical technique, applications, and limitations revisited. *Plast. Reconstr. Surg.* 105: 731, 2000.

Efficacy of Dermabond for Closing Lymphatic Leakage after Resection and OK-432 Treatment of a Lymphangioma

Sir:

Among postoperative complications after resection of lymphangiomas, lymphatic leakage from the skin incision causes considerable discomfort and sometimes results in secondary infection resistant to medical therapy.¹ Several studies suggest that the use of the tissue adhesive 2-octylcyanoacrylate (Dermabond; Ethicon, Inc., Somerville, N.J.) for closure of both traumatic lacerations and incisional surgical wounds results in a cosmetic outcome comparable to that achieved with conventional sutures.² Recently, Dermabond has been recognized for its usefulness in treating persistent cerebrospinal fluid leakage.³ In this report, we introduce the efficacy of Dermabond as a skin sealant for closing lymphatic leakage after partial resection of a lymphangioma.

A baby was delivered by cesarean section at 37 weeks' gestation with a huge, soccer ball-sized tumor located on the right lateral chest, extending to the right axillary region, right upper extremity, and anterior chest (Fig. 1). Computed tomography and magnetic resonance imaging demonstrated a multilocular cystic or cavernous tumor diagnosed as a mixed-type lymphangioma (Fig. 2). The tumor had not penetrated the chest wall or extended to the pleural cavity, but it had infiltrated deeply into the right upper extremity and axilla.

On the seventh day after birth, reduction surgery of the tumor, which was expanding from the axilla to lateral chest, was performed. The skin incisional wound was closed by subcutaneous 4-0 Vicryl (Ethicon) knot

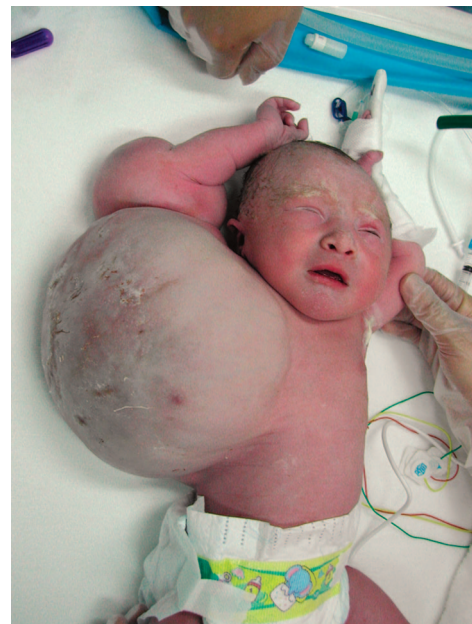

Fig. 1. Preoperative view of the huge, soccer ball-sized mass located on the right lateral chest and extending to the right axillary region, right upper extremity, and anterior chest.

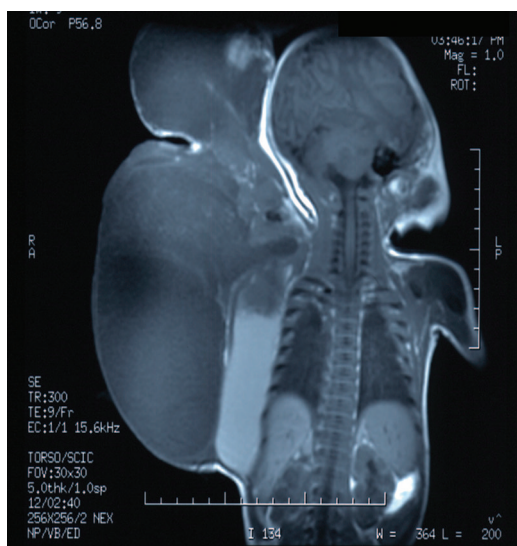


Fig. 2. Magnetic resonance imaging scan of the multilocular cystic or cavernous mixed-type lymphangioma infiltrating into the deep area of the right upper extremity and axilla. It was impossible to extirpate the tumor completely.

sutures followed by application of Dermabond. No drainage catheter was left in the operative field. Fluid collection increased gradually in the subcutaneous wound, and a little lymphatic leakage was seen from the skin incision. Dermabond was applied to protect the lymphatic leakage after several days. This bandage technique using Dermabond was very effective and was unaffected by lymphatic leakage postoperatively. Fourteen days after surgery, we performed OK-432 injection sclerotherapy.

There was obvious reduction in the size of the lesion and improvement in cosmetic appearance over the next few months. Moreover, there was no damage to the overlying skin and no scar formation. At 6 months of age, we performed reduction surgery for a lymphangioma of the upper extremity using intraoperative OK-432 injection for the remnant cystic lymphangioma. The skin incisional wound was sealed with Dermabond. The postoperative course was uneventful.

Dermabond has expanded the clinical options for wound closure.^{2,4} This alkyl ester monomer polymerizes in the presence of hydroxyl ions in water and blood, and is able to bind the edges of the epithelial layers of a wound.⁵ It is a nonabsorbable topical liquid and forms a thin, flexible, occlusive bandage without any signs of histotoxicity or adverse wound healing. In the present study, we applied Dermabond to close lymphatic leakage from the skin incisional wound after reduction surgery. Postoperatively, the Dermabond was unaffected by lymphatic leakage and OK-432 injection sclerotherapy was possible. There was no damage to the overlying skin and no scar formation. This Dermabond bandage technique was shown to be very effective for

closing lymphatic leakage after partial resection and OK-432 treatment of a lymphangioma.

DOI: 10.1097/PRS.0b013e31818823fa

Keiichi Uchida, M.D.

Mikihiro Inoue, M.D.

Kohei Otake, M.D.

Chikao Miki, M.D.

Masato Kusunoki, M.D.

Department of Pediatric Surgery
Mie University Graduate School of Medicine
Mie, Tsu, Japan

Correspondence to Dr. Uchida
Department of Pediatric Surgery
Mie University Graduate School of Medicine
Edobashi 2-174
Tsu, Mie 514-8507, Japan
ucchie@clin.medic.mie-u.ac.jp

DISCLOSURE

None of the authors has a financial interest in any of the products, devices, or drugs mentioned in this article.

REFERENCES

1. Uchida, K., Inoue, M., Araki, T., Miki, C., and Kusunoki, M. Huge scrotal, flank, and retroperitoneal lymphangioma successfully treated by OK-432 sclerotherapy. *Urology* 60: 1112, 2002.
2. Quinn, J., Wells, G., Sutcliffe, T., et al. A randomized trial comparing octylcyanoacrylate tissue adhesive and sutures in the management of lacerations. *J.A.M.A.* 277: 1527, 1997.
3. Rotenberg, B. W., Marchie, A., and Cusimano, M. D. Skin sealants: An effective option for closing cerebrospinal fluid leakage. *Can. J. Surg.* 47: 466, 2004.
4. Mattick, A., Clegg, G., Beattie, T., and Ahmad, T. A randomised, controlled trial comparing a tissue adhesive (2-octylcyanoacrylate) with adhesive strips (Steristrips) for paediatric laceration repair. *Emerg. Med. J.* 19: 405, 2002.
5. Hollander, J. E., and Singer, A. J. Laceration management. *Ann. Emerg. Med.* 34: 356, 1999.

Picayune? Peripherally Inserted Central Catheter Problems with Pectoralis Flaps

Sir:

Because of the reported greater safety, efficiencies in use, and lower cost of peripherally inserted central catheters, these devices have virtually replaced central venous catheters for short-term venous access and administration of parenteral therapies.¹ However, as with any invasive intervention, precautions must be heeded to minimize associated risks. Although symptomatic rates of venous thrombosis range from 1 to 4 percent, the actual risk of thrombosis of the cannulated vein, including the central veins, is far more prevalent if investigated by venography, even in up to 38 percent of patient encounters, with the cephalic vein by far the most likely to be involved.¹ More obviously, iatrogenic injuries as sequelae of peripherally inserted central

catheter line insertion have included median nerve bisection² and creation of a brachial arteriovenous fistula.³ Plastic surgeons have no privileged immunity, as the following case reminds us.

Following coronary artery bypass grafting in which bilateral internal mammary arteries were used as conduits, a frail, steroid-dependent, 64-year-old woman developed skin incision and sternal necrosis. After adequate debridement, a decision was made for coverage by advancing both pectoralis major muscles as extended island flaps⁴ based on their dominant thoracoacromial axis. Our usual muscle elevation and transposition, following skeletonization of small branches from the vascular pedicle to extend its reach, were in themselves uneventful.

During inset of the flaps, our anesthesia colleagues noted difficulty in administering drugs, which had been performed by means of a peripherally inserted central catheter line in the patient's right arm. Attempts to irrigate through or budge the line proved futile. We then carefully inspected the vascular pedicle of the right pectoralis major muscle. Indeed, a hemoclip placed by us across a small venous branch had a white piece of plastic snared in its center (Fig. 1). The distal-side hemoclip on what was apparently the cephalic vein was removed, and the infusion became unimpeded before the anesthesiologist easily removed the transected line. The proximal-side hemoclip was left in place to prevent a further disaster if a loose catheter should float into the heart itself. With trepidation, a venotomy was made in the cephalic vein remnant near where it entered the vein of the thoracoacromial axis. Back-bleeding was controllable, fortunately, so the line could be readily seen, grabbed, and completely retrieved (Fig. 2). Both sides of the cephalic vein were then suture-ligated. Comparatively speaking, the rest of her healing process was uneventful.

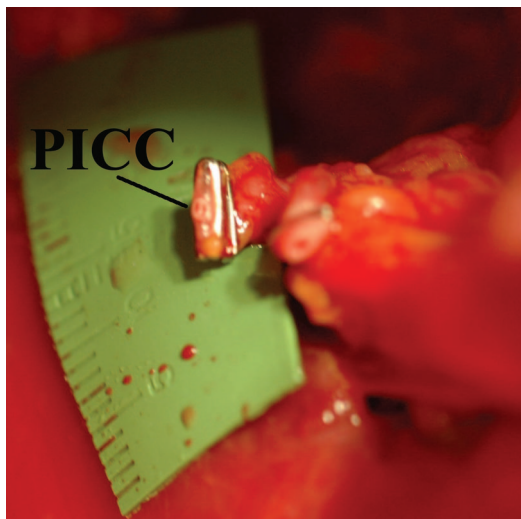

Fig. 1. The transected end of a peripherally inserted central catheter (PICC) line seen as a white circle within the hemoclipped cephalic vein.

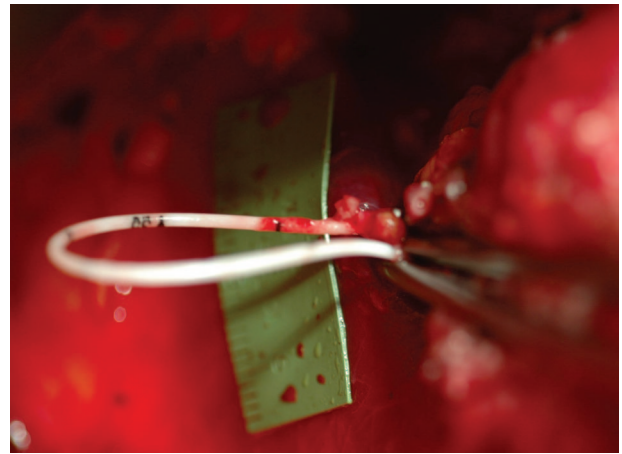


Fig. 2. Fortunately, through a venotomy in the cephalic vein remnant, the peripherally inserted central catheter line could be grabbed and retrieved.

Recitation of an anatomy lesson was in order. The cephalic vein, after following the deltopectoral groove, which is an excellent landmark for identifying the superior border of the pectoralis muscle where it coalesces toward its insertion, usually then accompanies the deltoid arterial branch of the thoracoacromial axis,⁵ perforates the costocoracoid membrane at the upper border of the pectoralis minor muscle, and finally empties into the axillary vein. How, then, did we go wrong? Do anomalies exist? Indeed, the cephalic vein sometimes courses anterior to the clavicle to penetrate the cervical fascia and end in the external jugular vein instead, or it can even be totally absent at this level. More pertinent to our misadventure, Reid and Taylor,⁵ in their cadaver studies of the vascular pedicle to the pectoralis major muscle, noted that actually more than 50 percent of the time the cephalic vein joined the thoracoacromial axis vein as a common trunk before entering the axillary vein. A lesson learned is that the Σ of pectoralis major muscle + cephalic vein + peripherally inserted central catheter line = a recipe for disaster for the unwary!

DOI: 10.1097/PRS.0b013e318186cd56

Randolph Wojcik, M.D.

Geoffrey G. Hallock, M.D.

Division of Plastic Surgery
The Lehigh Valley Hospital
Allentown, Pa.

Correspondence to Dr. Hallock
1230 South Cedar Crest Boulevard, Suite 306
Allentown, Pa. 18103
pbhallock@cs.com

REFERENCES

1. Allen, A. W., Megargell, J. L., Brown, D. B., et al. Venous thrombosis associated with the placement of peripherally inserted central catheters. *J. Vasc. Interv. Radiol.* 11: 1309, 2000.

2. Alomari, A., and Falk, A. Median nerve bisection: A morbid complication of a peripherally inserted central catheter. *J. Vasc. Access* 7: 129, 2006.
3. Tran, H. S., Burrows, B. J., Zang, W. A., and Han, D. C. Brachial arteriovenous fistula as a complication of placement of a peripherally inserted central venous catheter: A case report and review of the literature. *Am. Surg.* 72: 833, 2006.
4. Brutus, J. P., Nikolis, A., Perreault, I., Harris, P. G., and Cordoba, C. The unilateral pectoralis major island flap, an efficient and straightforward procedure for reconstruction of full length sternal defects after postoperative mediastinal wound infection. *Br. J. Plast. Surg.* 57: 803, 2004.
5. Reid, C. D., and Taylor, G. I. The vascular territory of the acromiothoracic axis. *Br. J. Plast. Surg.* 37: 194, 1984.

External Oblique Musculocutaneous Flap for Chest Wall Reconstruction

Sir:

Reconstruction of chest wall defects following extirpation of large locally recurrent breast tumors or radionecrosis after breast cancer treatment remains a challenge for the reconstructive and oncologic surgeon. The defects resulting from such resections are often quite large and could involve not only the skin and soft tissues but also the bone tissues (ribs and sternum), which require a strong chest wall reconstruction. This is essential for improving long-term survival and quality of life after radiation damage.

The majority of these defects can be repaired with the use of local and regional musculocutaneous or omental flaps. The use of the external oblique musculocutaneous flap to reconstruct the chest wall after these surgical treatments was first described in 1950 by Lesnick and Davids¹ and for coverage of the chest wall and pelvic defect by other authors.^{2,3}

From August of 2002 to June of 2005, nine patients underwent chest wall reconstruction with the external oblique musculocutaneous flap. They were referred to the Claudius Regaud Cancerology Institute for severe chest wall radionecrosis after breast cancer treatment ($n = 4$) or for locally recurrent breast cancer ($n = 5$). The mean chest wall defect covered with an external oblique myocutaneous flap measured 312 cm² (range, 152 to 595 cm²). There were neither major nor minor flap losses. The upper edge of the flap can reach the infraclavicular area and up to 5 cm beyond the midline, depending on the laxity of skin over the abdominal wall.⁴ It is a reliable vascular pedicle flap and provides a large area of vascularized fascia and cutaneous coverage. Thus, this flap can be an alternative and can be more easily used when the size of the defect cannot be covered by the latissimus dorsi. The arc of rotation to the specific zone of the chest wall is safe. The skin has the same aspect, the same color, and the same touch and offers a strong, thick coverage (Figs. 1 and 2). This flap is intended mainly for elderly patients because of the better laxity of the skin lacking in collagen fibers caused by aging. This flap provides comfort and a better quality of life compared with the need for daily medical

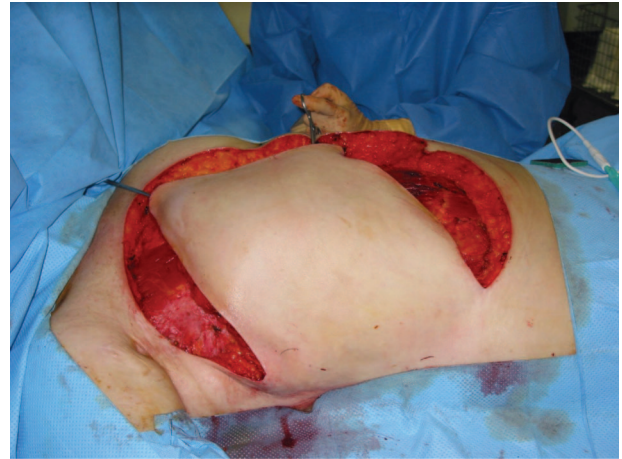

Fig. 1. Rotation of the flap.

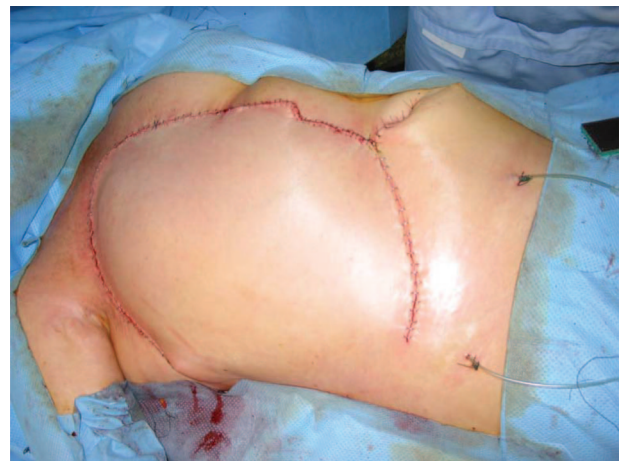

Fig. 2. Immediate postoperative view.

care with radiation-induced damage. There is no major loss of sensibility because the nerve supply of the muscle is preserved during dissection with the separation of the internal oblique muscle. Moreover, during surgery, there are no changes of position for the patient and the surgical team, and it is a relatively short operation (mean operative time, 100 minutes). The donor-site morbidity of the external oblique muscle flap appears to be quite minimal; the internal oblique and transverse muscles compensate for the functional loss of the external oblique muscle.

The main disadvantage of this flap is the rather unsightly, long abdominal scar, but there is no real problem of healing. We described local disunion treated by means of simple medical care ($n = 3$). Moreover, it does not allow breast reconstruction but only coverage of a plane. There is no sufficient volume and it is not possible to shape this strong flap. We described one case of Spigelian hernia.

We believe that the external oblique musculocutaneous flap is safe and reliable and allows for reconstruction of complex chest wall defects in the context

of a local recurrence of breast cancer or a radiation-induced lesion. There is no major morbidity or complications. The good clinical outcome is encouraging. DOI: 10.1097/PRS.0b013e318188240e

Amélie Gesson-Paute, M.D.

Gwenaél Ferron, M.D.

Ignacio Garrido, M.D.

Department of Surgical Oncology
Institut Claudius Regaud
Toulouse, France

Correspondence to Dr. Garrido
Department of Surgical Oncology
Institut Claudius Regaud
20-24 rue du Pont St Pierre
31052 Toulouse, France

REFERENCES

1. Lesnick, G. J., and Davids, A. M. Repair of surgical abdominal wall defect with a pedicled musculocutaneous flap. *Ann. Surg.* 137: 569, 1953.
2. Chang, R. R., Mehrara, B. J., Hu, Q. Y., Disa, J. J., and Cordeiro, P. G. Reconstruction of complex oncologic chest wall defect: A 10 year experience. *Ann. Plast. Surg.* 52: 471, 2004.
3. Moschella, F., and Cordova, A. A new extended external oblique musculocutaneous flap for reconstruction of large chest wall defect. *Plast. Reconstr. Surg.* 103: 1378, 1999.
4. Bogossian, N., Chaglassian, T., Rosenberg, P. H., and Moore, M. P. External oblique myocutaneous flap coverage of large chest wall defects following resection of breast tumors. *Plast. Reconstr. Surg.* 97: 97, 1996.

Microsurgical Vasovasostomy: A Combined Urologic and Plastic Surgical Approach

Sir:

Vasectomy is widely considered to be the most effective form of permanent contraception.¹ Approximately 100,000 men undergo this procedure each year in the United Kingdom.² An estimated 2 to 6 percent of men later seek vasectomy reversal.³ The first vasectomy reversal was performed in 1919, and in 1977 microsurgical techniques were introduced.⁴ Microsurgery is a skill that is taught in a formal setting and then requires regular practice to maintain. Of all the fields of surgery, plastic surgery is the one in which microsurgical skills are most often put into practice, and it has been shown that the best results in vasovasostomy are achieved by surgeons with training and ongoing experience in microsurgery.⁵

Ten patients underwent vasovasostomy over a 2-year period. The mean patient age was 43 years (range, 33 to 56 years), and the mean time from vasectomy was 8 years (range, 3 to 12 years). Patients were admitted on the afternoon of the procedure and discharged home the following morning. They were advised to abstain from ejaculation for 2 weeks but then to actively pursue fertilization.

Using general anesthetic, a single midline scrotal wound was used to deliver the testes and vasa. The

ligated ends of each vas were mobilized free of scar tissue and transected, and lumen patency was confirmed using a 0-0 Ethilon suture (Johnson & Johnson, New Brunswick, N.J.). Three equally spaced transmural sutures were then placed at the 2-, 6-, and 10-o'clock positions using 9-0 Ethilon under magnification with 3.5× optical loupes (Fig. 1). Interrupted 8-0 Ethilon sutures were then placed in the muscle and serosal layer (Fig. 2).

The testes and vasa were then replaced in the scrotal sac, with the dartos muscle and skin closed separately using Vicryl (Ethicon, Inc., Somerville, N.J.) and Op-Site spray (Smith & Nephew Health, London, United Kingdom) used as a waterproof dressing. Patients were fitted with a scrotal support before discharge the following day.

All patients were invited to submit a semen sample for analysis at 1 month after surgery. All patients had positive semen analysis, indicating vasal patency. No complications from surgery were reported.

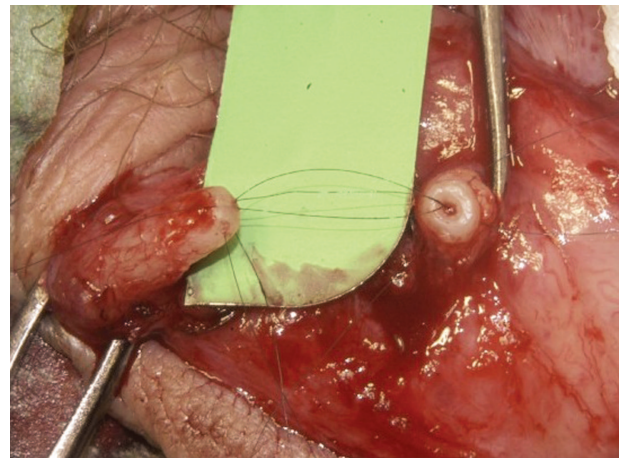


Fig. 1. The three 9-0 transmural Ethilon sutures in place.

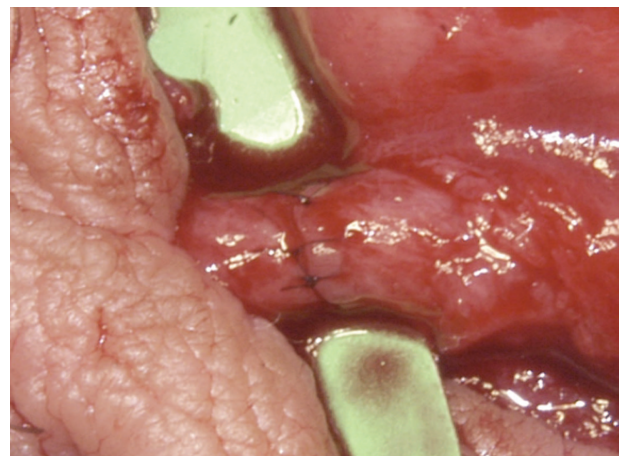


Fig. 2. The 8-0 Ethilon interrupted muscular layer sutures in place.

Vasovasostomy has a wide range of reported success rates. Undoubtedly, anastomosing the vasa is more technically challenging than a vascular anastomosis of similar dimensions, because of the narrow lumen and bulky, muscular wall. It stands to reason that the operator with the greatest ongoing experience with microsurgical work is likely to secure the highest success rate.

In our practice, the involvement of both a plastic surgeon and a urologist in vasovasostomy is deemed essential. The urologist receives referrals and is able to counsel the patient and his partner about the procedure, alternatives, risks, and factors governing male fertility generally. At surgery, the urologist delivers the vasa for the plastic surgeon to perform two-layer microsurgical anastomosis, and then acts as surgical assistant and finally closes the wound. The plastic surgeon has microsurgical prowess and is also able to perform vasoepididymostomy if necessary. We believe that the use of both surgeons for their specific areas of expertise is the key factor to our success rate.

DOI: 10.1097/PRS.0b013e318188244a

Rebecca L. E. Pollard, M.R.C.S.

Department of Plastic Surgery

Malcolm Crundwell, F.R.C.S.

Department of Urology

Chris Stone, F.R.C.S.(Plast.)

Department of Plastic Surgery
Royal Devon and Exeter Hospital
Exeter, Devon, United Kingdom

Correspondence to Dr. Stone
Department of Plastic and Reconstructive Surgery
Royal Devon and Exeter Hospital
Barrack Road
Exeter, Devon EX2 5DW, United Kingdom

REFERENCES

1. Vessy, M., Lawless, M., and Yeates, D. Efficacy of different contraceptive methods. *Lancet* 1: 841, 1982.
2. Fox, M. Vasectomy reversal: Microsurgery for best results. *Br. J. Urol.* 73: 449, 1994.
3. Holman, C. D., Wisniewski, Z. S., Semmens, J. B., Rouse, I. L., and Bass, A. J. Population-based outcomes after 28,246 in-hospital vasectomies and 1902 vasovasostomies in Western Australia. *Br. J. Urol. Int.* 86: 1043, 2000.
4. Silber, S. J. Perfect anatomical reconstruction of the vas deferens with a new microscopic surgical technique. *Fertil. Steril.* 28: 72, 1977.
5. Wood, S., Montazeri, N., Sajjad, Y., Troup, S., Kingsland, C. R., and Lewis-Jones, D. I. Current practice in the management of vasectomy reversal and unobstructive azoospermia in Merseyside & North Wales: A questionnaire-based survey. *Br. J. Urol. Int.* 91: 839, 2003.

The Use of External Hardware for Lower Extremity Free Flap Elevation

Sir:

Lower extremity reconstruction can be a challenge because of limited local soft-tissue options and a propensity for dependent swelling. Microvascular sur-

gery has enabled the coverage of more complex wounds and the salvage of severely traumatized extremities. Postoperative extremity elevation is vital to flap success, because it decreases edema and promotes venous return. The surgeon must also avoid an equinus deformity in the recipient leg.

External fixation and orthopedic pins have been described for elevation and immobilization of cross-extremity flaps and pedicled flaps.¹⁻⁴ They can also be used for cases of free flap reconstruction in which the patient has not sustained a fracture, such as in the microsurgical reconstruction of posterior heel defects.⁵ We present an effective method of ensuring adequate elevation and immobilization of the free flap–reconstructed lower extremity, which can also be adapted to prevent an equinus deformity.

A 54-year-old woman sustained a crush injury of the right lower extremity with open calcaneal fractures that were treated with cortical screws. The wound was eventually reconstructed with a rectus abdominis free flap and application of an external fixator across the ankle joint to aid in elevation and to prevent an equinus deformity. The external fixator was removed in the office 3 weeks later.

From 2000 to 2006, we applied an external fixator or pins to the lower extremity in seven patients during free flap placement who did not otherwise require hardware for fracture fixation. The extremity was then elevated by using rolls of gauze dressing at adjustable lengths to attach the hardware to a trapeze apparatus over the bed (Fig. 1).

Four patients had external fixators placed and three patients had pins inserted. The free flaps included one anterolateral thigh flap, three rectus abdominis flaps, and three latissimus dorsi flaps. All flaps survived. One patient developed a pin-site infection 2 months postoperatively that necessitated removal of the hardware. The fixator had been left in place because of a popliteal wound next to the free flap. Otherwise, there were no other hardware-related complications.

Although we regularly use a patient's existing external hardware to aid in lower extremity elevation, electively applying an external fixator or orthopedic pins in lower extremity free flap reconstructions, when the hardware is not required for bony fixation, is a novel method with which to facilitate elevation of the extremity. The hardware should be placed by an orthopedic surgeon, with the plastic surgeon determining the optimal placement of pins. The reconstructive team should be intimately involved at this time, because injury to the flap by poor tissue handling can occur. The fixation allows for elevation of the lower extremity in a trapeze over the hospital bed, thereby limiting edema of the extremity and venous compromise of the free flap. A rehabilitation shoe can be strapped to the external fixator to prevent foot drop (Fig. 1), or an external fixator spanning the ankle joint can prevent the development of an equinus deformity. Monitoring of the free flap is facilitated because the flap does not have

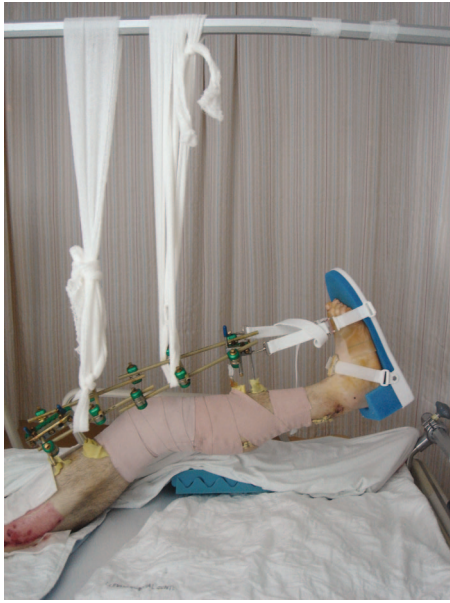

Fig. 1. Elastic bandage–wrapped free flap covering a knee defect with an external fixator in place. The patient did not have a fracture that required external fixation. In this patient, the rehabilitation shoe was attached to the hardware to maintain ankle dorsiflexion. The leg was wrapped with an elastic bandage because the patient had started progressive dangling and elastic bandage wrapping as part of his postoperative rehabilitation.

to be covered by bulky dressings. The hardware is easily removed in an outpatient setting. When performing lower extremity reconstructions, use of external hardware may assist in the ability to reduce swelling, ease dressing and wound care, limit risk of equinus deformity, improve patient compliance, and expedite advancement to rehabilitation therapy.

DOI: 10.1097/PRS.0b013e3181882423

Christine Rohde, M.D.

Columbia University Medical Center
New York-Presbyterian Hospital

Brittney Williams

Jamie P. Levine, M.D.

Institute of Reconstructive Plastic Surgery
New York University Medical Center
New York, N.Y.

Correspondence to Dr. Levine
530 First Avenue, Suite 8V
New York University Plastic Surgery Associates
New York University Medical Center
New York, N.Y. 10016
levinj04@med.nyu.edu

DISCLOSURE

None of the authors has a financial interest in any of the materials, products, or devices discussed in this article.

REFERENCES

1. Evans, G. A., Bang, R. L., Cornah, M. S., et al. The value of the Hoffman skeletal fixation in the management of cross-leg flaps, particularly those complicated by open fractures of the tibia. *Injury* 11: 110, 1979.
2. Stern, O. S. New fixation device for cross-leg flaps. *Plast. Reconstr. Surg.* 50: 194, 1972.
3. Mooney, J. F., DeFranzo, A., and Marks, M. W. Use of cross-extremity flaps stabilized with external fixation in severe pediatric foot and ankle trauma: An alternative to free tissue transfer. *J. Pediatr. Orthop.* 18: 26, 1998.
4. Nappi, J. F., and Drabyn, G. A. External fixation for pedicle-flap immobilization: A new method providing limited motion. *Plast. Reconstr. Surg.* 72: 243, 1983.
5. Buford, G. A., and Trzeciak, M. A. A novel method for lower-extremity immobilization after free-flap reconstruction of posterior heel defects. *Plast. Reconstr. Surg.* 111: 821, 2003.

A Novel Vascular Reconstruction Technique for Limb Salvage Surgery Using Temporary Bypass Tubes

Sir:

The techniques and concepts of limb salvage for soft-tissue sarcoma of the lower limb involving major vessels have been substantially developed in recent years.^{1–3} We present a novel vascular reconstruction technique for limb salvage surgery using temporary bypass tubes.

A temporary bypass tube (Anthron; Toray Industries, Tokyo, Japan) has been designed for use before excision of soft-tissue sarcoma involving major vessels in the extremities. The tube is constructed of polyvinylchloride coated with a heparinized hydrophilic polymer (Anthron).⁴ The rate of heparin release from the polymer is 10^{-2} U/cm²/minute, sufficient to prevent intracatheter coagulation without requiring administration of systemic anticoagulants. Both ends of the tube are tapered to facilitate insertion of the bypass tube into vessels.

Nambisan and Karakoisis² showed the standard steps in extensive resection of sarcoma of the extremity involving major vessels. After proximal and distal exposure of the vessels, dissection around the muscles to be removed along with the tumor is undertaken, and the origins and insertions of these muscles are divided. The last step in resection, following heparinization, is to clamp and divide the vessels proximally and distally. We used to perform the operation in the same manner described by Nambisan and Karakoisis.² However, we encountered several cases in which control of hemorrhage from soft tissue surrounding the tumor was difficult. We therefore attempted to use temporary bypass tubes before and during extirpation of the whole tumor (Fig. 1). This procedure provided an almost bloodless field during dissection. This bypass procedure using an Anthron tube served as a pneumatic tourniquet to which we have become accustomed, facilitating reductions in hemorrhage, easy dissection, and time savings. Finally, this maneuver provides a lower incidence of

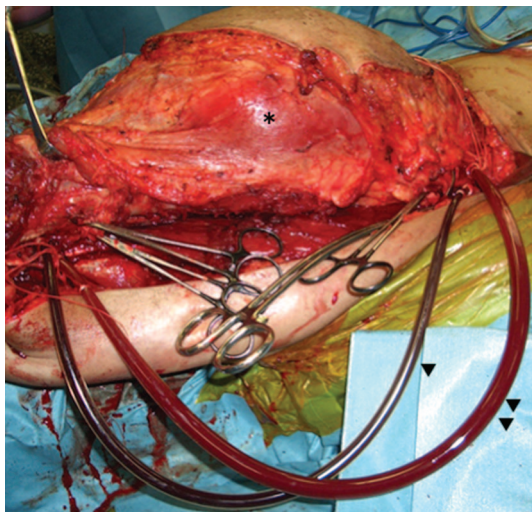


Fig. 1. A large liposarcoma in the anterior region of the right thigh (asterisk). Anthron bypass tubes were substituted for the superficial femoral artery (single arrowhead) and vein (double arrowheads).

infection, which can be quite high during extensive resections that require prolonged surgery. However, the tube courses beyond the operative field, and the natural warp of the tube serves to keep the tube away from the tumor still connected around abundant soft

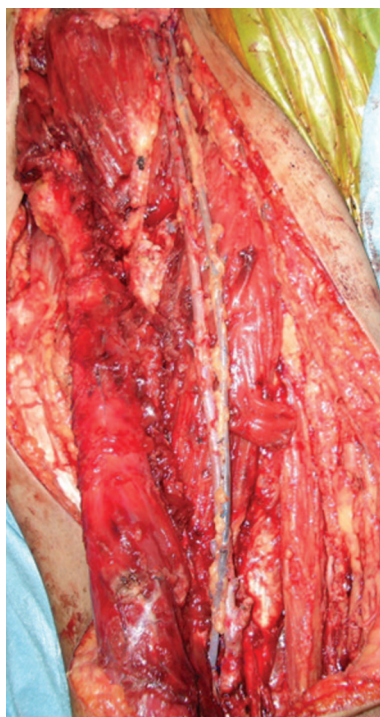


Fig. 2. After extirpation of the tumor keeping with bypass, the contralateral greater saphenous vein is harvested. Vascular defects of the superficial femoral artery vein were reconstructed using vein grafts.

tissue. This facilitates handling during tumor dissection. After extirpation of the tumor keeping with bypass, the contralateral greater saphenous vein is harvested. Vascular defects are reconstructed using vein grafts (Fig. 2). During vein harvesting and graft preparation, there was no concern regarding limb ischemia.

The tapered type tube can maintain blood flow at 230 ml/minute under a 20-cm H₂O blood pressure discrepancy. Given the high blood flow through the femoral artery, holding the inserted tube and vessels by anchoring them with thick silk sutures and clamping them with bulldog forceps is a key step to achieving success in this procedure. No thrombus formation in the catheter was detected after use and no complications attributable to the catheter were observed.

Limb salvage surgery using the Anthron bypass tube facilitates reductions in ischemia time, operation time, and infection rate. We have proposed a new technique with which to obtain a bloodless operative field in the proximal extremity using the bypass tube. This technique appears useful for resecting tumors with adequate surgical margins and achieving local control of the disease.

DOI: 10.1097/PRS.0b013e31818823e6

Noriaki Kikuchi, M.D., Ph.D.

Division of Plastic and Reconstructive Surgery
Department of Orthopaedic Surgery

Toshihisa Osanai, M.D., Ph.D.

Department of Orthopaedic Surgery

Takashi Tsuchiya, M.D., Ph.D.

Department of Orthopaedic Surgery
Yamagata University School of Medicine

Hiroshi Orui, M.D., Ph.D.

National Sanatorium of Yamagata Clinic

Toshihiko Ogino, M.D., Ph.D.

Department of Orthopaedic Surgery
Yamagata University School of Medicine
Yamagata, Japan

Correspondence to Dr. Kikuchi
Department of Orthopaedic Surgery
Yamagata University School of Medicine
2-2-2 Iidanishi
Yamagata 990-9585, Japan
nkikuchi@med.id.yamagata-u.ac.jp

Presented at the Annual Meeting of the Japanese Society of Reconstructive Microsurgery, in Kumamoto, Japan, October 14 through 15, 2004, and at the Annual Musculoskeletal Tumor Meeting of the Japanese Orthopaedic Association, in Sapporo, Hokkaido, Japan, July 6 through 7, 2006.

REFERENCES

- Fortner, J. G., Kim, D. K., and Shiu, M. H. Limb-preserving vascular surgery for malignant tumors of the lower extremity. *Arch. Surg.* 112: 391, 1977.
- Nambisan, R. N., and Karakois, C. P. Vascular reconstruction for limb salvage in soft tissue sarcomas. *Surgery* 101: 668, 1977.
- Kawai, A., Hashizume, H., Inoue, H., Uchida, H., and Sano, S. Vascular reconstruction in limb salvage operation for soft tissue tumors of the extremities. *Clin. Orthop.* 332: 215, 1999.

4. Nakao, A., Nonami, T., Hrada, A., Kasuga, T., and Takagi, H. Portal vein resection with a new antithrombogenic catheter. *Surgery* 108: 913, 1990.

Erbium:Yttrium-Aluminum-Garnet Laser Debridement of Chronic Wounds

Sir:

Chronic wounds are a major health problem that affects millions of people annually. The total number of chronic wounds in the population seems to be increasing nowadays, probably because of an increasing elderly population, and some illnesses with an elevated incidence in modern society are often recognized as a physiopathologic substratum.

The erbium:yttrium-aluminum-garnet (YAG) laser has been widely used for various clinical procedures, such as caries removal, bacterial decontamination and cavity preparation, soft-tissue surgery, removal of dental calculus, and care of periodontopathy.^{1,2} Analyzing the results of erbium:YAG laser use in odontology,³ a treatment protocol for laser debridement of chronic wounds was developed for patients who, for more than 3 months, did not respond to conventional curettage and the application of an advanced medication based on oxidized regenerated cellulose and collagen. Chronic wounds remain among the most costly unsolved problems in health care today. Moreover, in this patient group, the traditional mechanical curettage was the cause of intense pain (Figs. 1 and 2).

Thirty patients (18 women and 12 men; mean age, 67 years; range, 56 to 78 years) with chronic wounds that did not heal with conventional therapies who had already been treated with an advanced medication based on oxidized regenerated celluloses and collagen were treated using the erbium:YAG laser for debridement. The laser treatment was carried out using the

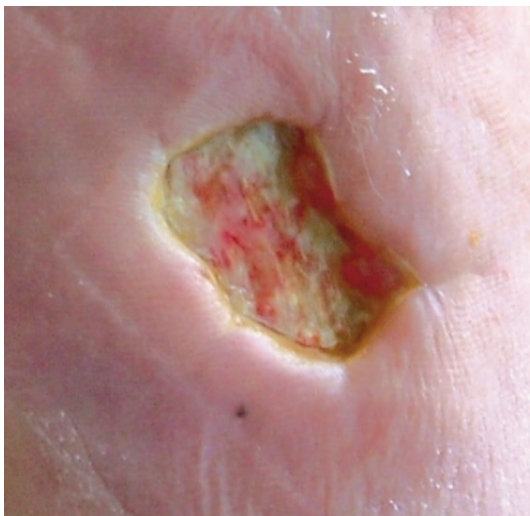

Fig. 1. Pretreatment view of a chronic wound on the sole of the foot in a 57-year-old patient after a stingray injury.

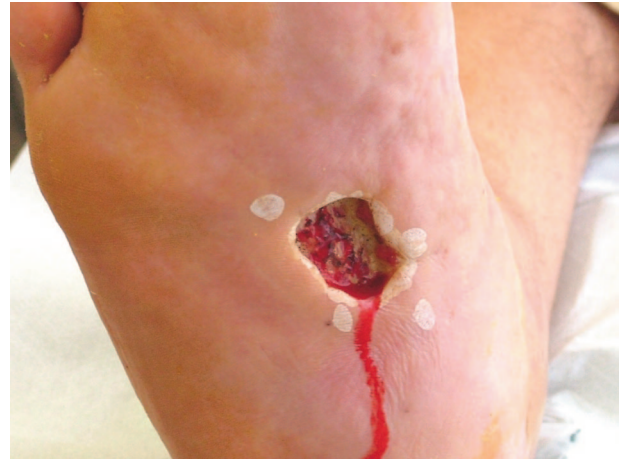

Fig. 2. Immediate posttreatment view.

Smart2940Dplus erbium:YAG laser manufactured by DEKA srl (Firenze, Italy) (settings: pulse energy, 300 mJ; pulse repetition rate, 10 Hz; spot size, 3 mm; and pulse duration, 350 μ sec). The ablation was performed until bleeding of the tissues was noted. After that, the wound was covered with an advanced medication based on oxidized regenerated celluloses and collagen (Promogran; Ethicon, Inc., Somerville, N.J.) followed by the application of the same medication based on oxidized regenerated cellulose and collagen.

The laser treatment of ulcers is much less painful than conventional care. At the end of the erbium:YAG laser treatment, the result is bleeding with the production of blood-borne growth factors and removal of senescent cells and bacteria. After 7 days, lesions appear in the active healing phase, with an advancing epithelial edge and increasing granulation tissue. After 14 days, the lesion is confirmed again to be in the advanced resolution phase.

Complete healing of lesions has been obtained in 90 percent of the patients who continued with the use of advanced medications over a mean period of 2.5 months. Grafts or local flaps were used in the remainder of patients.

Treatment of chronic wounds with the erbium:YAG laser produces an optimal and painless debridement compared with conventional techniques, and probably stimulates (together with advanced medication) the activation and proliferation of fibroblasts by means of multiple mechanisms. From the results of this study, it is evident, as shown by the *in vitro* observations, that the erbium laser notably stimulates fibroblast activation and mitogenesis⁴ and collagen synthesis and deposition.⁵ In addition, laser debridement has an enormous advantage in comparison with traditional care, because it enables the preparation of a sterile and bloody wound bed and eliminates with precision the necrotic debris and fibrous tissue.

Treatment of chronic wounds using the erbium:YAG laser reduces costs, because healing time is notably reduced in comparison with traditional care. These

results have to be confirmed by a large, multicenter study group.

DOI: 10.1097/PRS.0b013e318186ccf2

Paolo Mezzana, M.D.

Maria Giuseppina Onesti, M.D.

Mariangela Ciotti, M.D.

Gerardo Malzone, Jr.

Nicolò Scuderi, M.D.

Department of Plastic and Reconstructive Surgery
University of Rome "La Sapienza"
Rome, Italy

Correspondence to Dr. Mezzana
Via Merulana 61/A
00185 Rome, Italy
pmezzana@yahoo.it

REFERENCES

1. Crespi, R., Barone, A., and Covani, U. Histologic evaluation of three methods of periodontal root surface treatment in humans. *J. Periodontol.* 76: 476, 2005.
2. Aoki, A., Ando, Y., Watanabe, H., and Ishikawa, I. In vitro studies on laser scaling of subgingival calculus with an erbium: YAG laser. *J. Periodontol.* 65: 1097, 1994.
3. Cranska, J. P. Do all dentists use lasers? *Dent. Today* 25: 112, 2006.
4. Pourzarandian, A., Watanabe, H., Ruwanpura, S. M., Aoki, A., and Ishikawa, I. Effect of low-level Er:YAG laser irradiation on cultured human gingival fibroblasts. *J. Periodontol.* 76: 187, 2005.
5. Dang, Y., Ren, Q., Ma, H. J., and Zhang, J. Effects of the 1.320 nm Nd:YAG laser on transepidermal water loss, histological changes, and collagen remodelling in skin. *Lasers Med. Sci.* 21: 147, 2006.

Challenges in Reconstructive Surgery: Management of "Bride Burning"

Sir:

"Bride burning" is a social phenomenon in countries such as India, Pakistan, and Bangladesh affecting thousands of young women every year.^{1,2} The ideal situation for these patients would be treatment in specialized facilities within the first month after injury. However, those few who survive are often referred 6 months to 2 years later and have, at this time, horrible disfigurements and functional limitations that keep them away from a correct reinsertion into society. In these cases, the challenge for plastic surgeons is to give them back the possibility of a dignified life.³

A 21-year-old Pakistani dancer who presented to us is a classic case of bride burning. Her husband, a local prince, repudiated the woman because of jealousy and burnt her in January of 1999 by throwing sulfuric acid on her face, neck, trunk, and arms. The resulting disfigurement and retractions destroyed her normal aesthetic appearance and completely impaired her neck movements (Fig. 1). From November of 1999 to September of 2005, we performed 14 reconstructive procedures to correct the anatomical and functional defects.

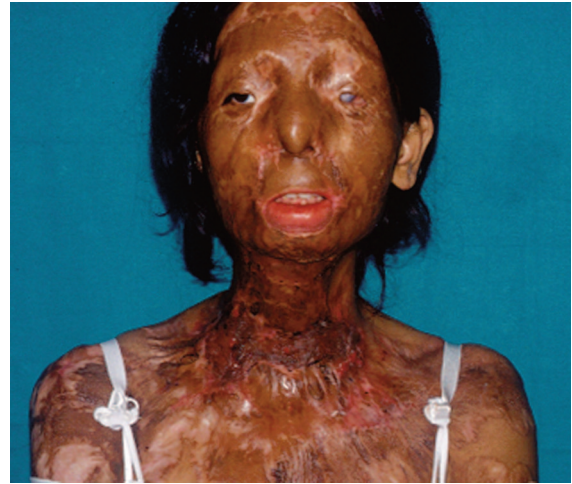

Fig. 1. Preoperative view of the patient in September of 1999.

Different techniques were used in the face to correct complex scars situated in almost all regions. We used skin grafts, skin expanders, and Z and V-Y flaps to (1) expand the amount of skin available, (2) reconstruct it in zones where it was completely replaced by scars, and (3) interrupt the tension effect of retractions that limited movement. The inner canthus was managed with an inner canthoplasty ("dancing men" technique), the nasolabial area was managed with a Z flap to achieve an elongation in the direction of the natural groove, and the area between the nostrils and columella was managed with a V-Y flap.

The reconstruction of the ear, a real challenge in plastic surgery, is usually performed with either of two techniques: autologous cartilage transplant or the use of implants. The latter has the advantages of stability, easy execution, low operative risks, minimal complication rate, better aesthetic result, and minor number of operations required; the disadvantages include continuous strict implant hygiene, sensibility loss, and possible patient refusal. We preferred implant reconstruction because of the experience gained in our institutions using this technique. Three screws were inserted in the mastoid region, behind the external acoustic meatus, sufficient to hold the auricular implant in place.

Neck and arm contractures did not pose particular problems and were dealt with using Z-plasty techniques, insertion of expanders, and skin grafting. Post-operative physical rehabilitation was essential in preventing the formation of new contractures.

Tissue damage caused by acids is similar to that resulting from thermal injuries but often requires a greater number of operations to yield acceptable aesthetic and functional results.³ Different parameters (e.g., scar type, extension, anatomical side, patient age, and gender) influence indications and surgical planning. In these complex cases of contracture and disfigurement, plastic surgeons must perfectly manage all available techniques of reconstruction and perform

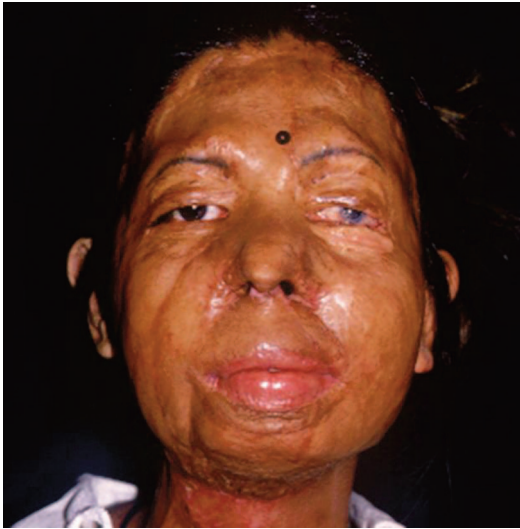

Fig. 2. Final aesthetic appearance in October of 2005 after reconstructive operations.

multiple operations over a period of years to provide an acceptable and dignified social life to the affected patient (Fig. 2).

DOI: 10.1097/PRS.0b013e318186ccdb

Antonino Araco, M.D.

Gianpiero Gravante, M.D.

Francesco Araco, M.D.

Department of Surgery

Pietro Gentile, M.D.

Valerio Cervelli, M.D.

Department of Plastic Surgery

University of Tor Vergata

Rome, Italy

Correspondence to Dr. Gravante

Via U. Maddalena 40/a

00043 Ciampino, Rome, Italy

ggravante@hotmail.com

REFERENCES

1. Begum, A. A. Acid violence: A burning issue of Bangladesh. Its medicolegal aspects. *Am. J. Forensic Med. Pathol.* 25: 321, 2004.
2. Kumar, V., and Kanth, S. Bride burning. *Lancet* 364(Suppl. 1): s18, 2004.
3. Micheau, P., Lauwers, F., Vath, S., Seilha, T., Dumurgier, C., and Joly, B. Caustic burns: Clinical study of 24 patients with sulfuric acid burns in Cambodia. *Ann. Chir. Plast. Esthet.* 49: 239, 2004.

Transoral Endoscopically Assisted Closure of Cleft Palate in Foals

Sir:

The repair of cleft palate in foals has been compared with that in humans regarding importance. Because of

the anatomical differences in the oropharynx and hypopharynx between horses and humans, clefting in equines results not only in an insufficient absorption of nutrients by nasal milk escape but also, following aspiration, in a life-threatening aspiration pneumonia.

Current reports suggest that cleft palate repair in foals is technically difficult and is accompanied by a high complication rate. Despite successful cleft repair, aspiration pneumonia existing before the operation can be fatal.¹

The distance between a foal's front teeth and palate is too large for a transoral approach such as that performed in humans. Until now, therefore, an extraoral access was applied by means of a symphysiotomy of the mandible, often in combination with a pharyngotomy. Thus, the vast soft-tissue wound led predominantly to uncontrollable infections and asphyxia.²⁻⁴ To avoid these complications, we decided to take a transoral approach using endoscopic instruments and technologies to bridge the distance.

In a 5-week-old stallion, milk outflow off the nose during sucking was observed from birth. Increasing inflammation parameters and subtotal lung field shadowing in the lateral chest radiograph proved the diagnosis of an aspiration pneumonia. The endoscopic investigation of the oropharynx confirmed the suspicion of palatoschisis in the form of an uvula bifida and a submucous cleft palate (Fig. 1). After suitable presurgical preparation, the surgical procedure was performed with the foal in back position under general anesthesia. Because of the limited overview of the transoral approach performed, endoscopic optics were introduced to provide a view control on a screen during the proceedings. Thus, by the far less traumatic, endoscopically assisted transoral approach, the problem of exposure of the operative field was managed easily. Analogous to the setup of cleft palate repair in humans, we performed an intravelar myoplasty of the levator veli palatini muscle.

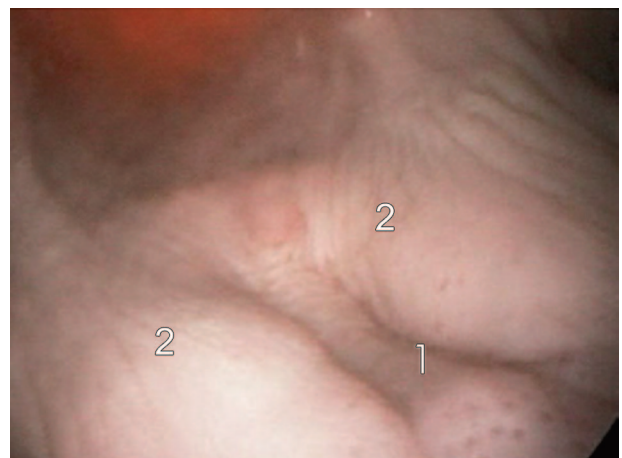


Fig. 1. Endoscopic view of the submucous cleft palate. 1, Submucous cleft palate with visible vomer; 2, lateral border of the cleft with a belly-like concavity falsely inserting into the levator veli palatini muscle.

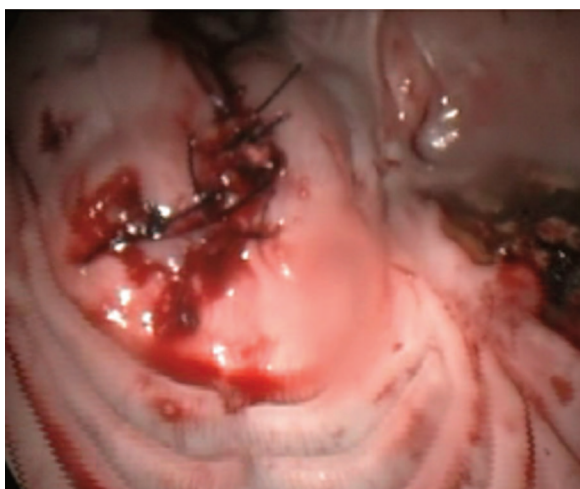

Fig. 2. Closure of the oral layer at the end of the operation.

palatini muscle in the foal according to Kriens.⁵ Until now, this procedure has not been applied explicitly to horses, probably because when the function of the levator palatini muscle in horses is discussed, there is controversy regarding the active raising of the extremely long soft palate.³ However, a layer-wise closure of the cleft palate should decrease sore healing disturbances with dehiscences and raise the static stability of the palate. After closure of the oral layer with 2-0 and 3-0 resorptive sutures (Fig. 2), the foal recovered well from anesthesia. After postsurgical treatment, the foal was returned to the mother and was able to drink normally. After antibiotic therapy with gentamicin and Veracin, at 8 days postoperatively, the lateral chest radiograph proved clearly falling findings. The inspection of the situs showed at that time a “first-in, first-out” sore healing. The foal developed normally up to the last control, 12 months postoperatively. Nevertheless, the precise value of this surgical technique must be evaluated based on the results in other cases.

DOI: 10.1097/PRS.0b013e318186cd1b

Heico-Rüdiger Krause, Ph.D.

Klinik für Mund-, Kiefer-und Gesichtschirurgie
Plastische Operationen
Spezielle Schmerztherapie
Klinikum Bremen-Mitte
Bremen, Germany

Marc Koene, D.V.M.

Tierärztliche Klinik für Pferde
Lüsche, Germany

Jan Rustemeyer, M.D.

Klinik für Mund-, Kiefer-und Gesichtschirurgie
Plastische Operationen
Spezielle Schmerztherapie
Klinikum Bremen-Mitte
Bremen, Germany

Correspondence to Dr. Rustemeyer
Klinik für Mund-, Kiefer-und Gesichtschirurgie
Klinikum Bremen Mitte
28177 Bremen, Germany
janrustem@t-online.de

DISCLOSURE

The authors have no conflicts of interest.

REFERENCES

1. Jones, R. S. Surgical repair of cleft palate in the horse. *Equine Vet. J.* 7: 86, 1975.
2. Bowman, K. F., Tate, L. P., Jr., Evans, L. H., and Donawick, W. J. Complications of cleft palate repair in large animals. *J. Am. Vet. Med. Assoc.* 180: 652, 1982.
3. Heffron, C. J., Baker, G. J., and Lee, R. Fluoroscopic investigation of pharyngeal function in the horse. *Equine Vet. J.* 11: 148, 1979.
4. Kirkham, L. E., and Vasey, J. R. Surgical cleft soft palate repair in a foal. *Aust. Vet. J.* 80: 143, 2000.
5. Kriens, O. Fundamental anatomic findings for an intravelar veloplasty. *Cleft Palate. J.* 7: 27, 1970.

Inlay Technique for Large Skin Graft Replacement in the Small Animal

Sir:

Advances in plastic surgery and immunology have resulted in many experimental studies involving transplantation of both vascularized and nonvascularized bone, muscle, nerve, and skin. Rats are preferred for their affordability, easy handling, and robustness in many experimental models. Skin graft harvesting and placement in the rat body are difficult procedures because of the small size of the animal. Only one graft replacement method¹ and few skin graft harvesting techniques^{2,3} have been reported in the literature.

The tie-over dressing is the standard method of skin graft replacement used in a rat model. The tie-over dressing reduces the amount of dead space, prevents hematoma formation, and immobilizes the grafts,⁴ maintaining close contact between graft and basement. We observed that the tie-over dressing caused elevation of graft edges because of the rat's loose skin and disrupted the connection between graft and basement, resulting in partial graft necrosis. We discovered that the tie-over dressing has a negative impact on small grafts (2 × 2 cm) and caused total graft necrosis. The tie-over dressing is uncomfortable for the rat and caused the rat to destroy its dressing. Furthermore, the tie-over dressing of large skin grafts was associated with increased immobilization and resulted in nutrition deficiency, hygiene problems, and graft infection.

An inlay technique for protection of skin and composite grafts in experimental animals has been described.¹ With this technique, the replacement graft under the skin is protected from external trauma and demonstrates excellent vascularity. However, a disadvantage of this technique is that it is limited to small grafts. In our transplantation studies, the inlay technique serves as a guide for skin graft placement. However, in our experience, this technique has provided excellent results, even with placement of large skin grafts.

We have applied this technique in an allograft transplantation study in which a large full-thickness skin

graft (8 × 8 cm) was harvested from a Lewis-Brown Norway rat. Next, the skin of the recipient Lewis rat was incised in the lateral thoracoabdominal region, and the skin was undermined in preparation for graft placement. Multiple holes were made in the graft to permit drainage of seroma or hematoma from under the graft. Stretched grafts were sutured into the bed of the thoracoabdominal muscle and fascia using absorbable suture (Fig. 1, *above*). Then, the previously undermined skin flaps were sutured together over the graft, covering it completely. After 5 days, the overlying skin flaps of the recipient graft were reopened through the original incision and the serous exudates were evacuated. At this time, many graft hairs were noted to have fallen from the skin. We determined that the grafts had all integrated with the background and were viable; minimal graft edge necrosis was noted in a few rats. The overlying recipient skin was excised in proportion to the size of the accepted skin graft. Next, grafts were exteriorized, and the refreshed skin edges of the recipient and the graft were sutured together using nonabsorbable

suture. New hair growth was noted on the graft surface at 1 month after transplantation (Fig. 1, *below*).

The advantages of the inlay technique include the fact that it provides close contact between the graft surface and the background without need for a tie-over dressing. Whereas the graft in the tie-over dressing technique is sutured to recipient skin, which makes it prone to edge elevation, in the inlay technique, stretch closure of the graft provides immobilization. Another advantage of the inlay technique is that skin covering the graft is innervated, protecting the graft from auto-cannibalism. Finally, we have not observed any problems with rat mobilization, no infection was observed, and no additional dressing material was needed.

In conclusion, the inlay technique may be used with confidence for placement of large skin grafts in the small-animal model. This method causes minimal post-operative stress to the rat and reduces morbidity in transplantation studies where exhausting therapies with immunosuppressive drugs are used and can compromise graft acceptance.

DOI: 10.1097/PRS.0b013e318186cd2f

Serdar Nasir, M.D.

Lukasz Krokowicz, M.D.

Mehmet Bozkurt, M.D.

Maria Siemionow, M.D.

Cleveland Clinic Foundation
Cleveland, Ohio

Correspondence to Dr. Siemionow
Cleveland Clinic Foundation
Department of Plastic Surgery
9500 Euclid Avenue, A60
Cleveland, Ohio 44195
siemiom@ccf.org

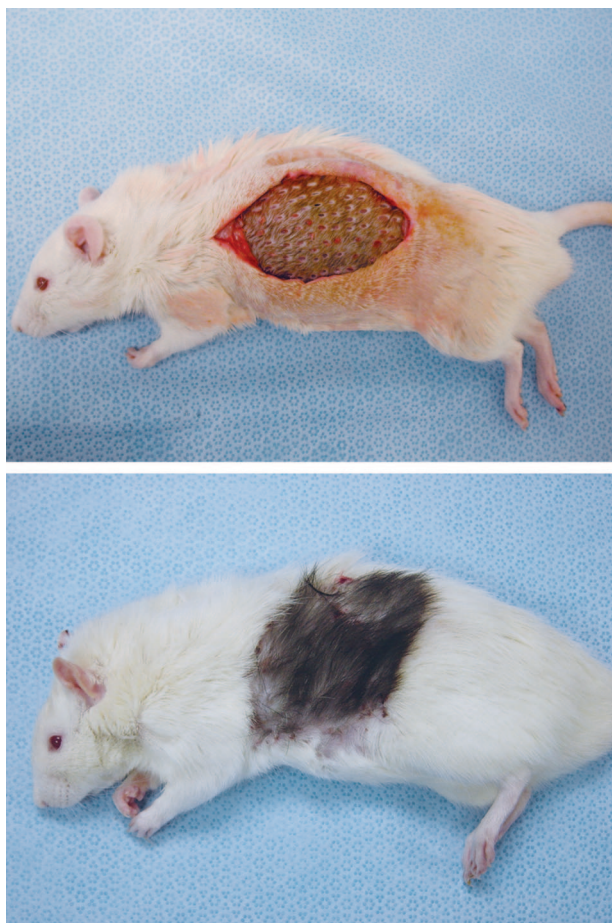


Fig. 1. (*Above*) The inlay technique for large skin graft replacement. The skin graft is placed on the thoracoabdominal muscle and the fascia is placed under the recipient. (*Below*) View of the transplanted skin allograft at 1 month after transplantation with evidence of hair regrowth.

REFERENCES

1. Erol, O. O., and Spira, M. Inlay technique for protection of skin and composite grafts in experimental animals. *Plast. Reconstr. Surg.* 64: 271, 1979.
2. Woodruff, M. F., and Simpson, L. O. Experimental skin grafting in rats; with special reference to split skin grafts. *Plast. Reconstr. Surg.* 15: 451, 1955.
3. Tsur, H. Split thickness skin grafts from rats: A simple technique. *Br. J. Plast. Surg.* 29: 341, 1976.
4. Rudolph, R., and Ballantyne, D. Skin grafts. In J. G. McCarthy (Ed.), *Plastic Surgery*. Philadelphia: Saunders, 1990. Pp. 240–241.

A Simple Device for the Application of Medicinal Leeches

Sir:

The use of medicinal leeches is an ancient craft first recorded in Eighteenth Dynasty Egypt.¹ In modern medicine, the use of *Hirudo medicinalis* has become the standard of care in the nonoperative treatment of venous congestion following microvascular free tissue transfer and replantation, as leech saliva contains potent anticoagulants and antiplatelet substances.²

Leech handling can be difficult and unsettling for many, particularly for staff who are not experienced with the procedure. Furthermore, directing leech attachment to the appropriate area can be time consuming and adventuresome. It is not uncommon to have the leech application process take 20 to 30 minutes of an intensive care nurse's time that could obviously be better spent elsewhere in patient care. Considering that some congested transfers require several days of frequent leech applications until neovascularization, it is easy to comprehend the time and economical burdens of leech therapy.

Leeches can migrate to distant sites such as body orifices or deeper into the wound. Granzow describes a device for leech control after placement, the "leech leash," which uses a surgical suture passed through the leech and is then tied to the dressing to prevent migration.³ Leech application devices reported in the literature include a tapered segment of a Yankauer tube, as described by MacQuillan et al.,⁴ and the "leech cage," as described by Tan and Atik.⁵

We present a simple method for leech guidance and application that we have found very effective. We use a standard medicinal leech, *Hirudo medicinalis*, as supplied by the hospital pharmacy. A single, 2 × 2-inch gauze pad is placed deep in a 3-cc syringe and topped by a small piece of petroleum-impregnated gauze (Fig. 1). The leech is then easily placed into the syringe and covered with gauze for transportation to the patient. Next, the opening of the 3-cc syringe applicator is placed directly over the desired site of attachment, such as the nail bed or finger pulp. The leech seems repelled by the petroleum-impregnated gauze and can easily turn 180 degrees in the applicator. The leech moves down the tube and attaches to the desired site (Fig. 2). Once attachment is complete, the device is easily withdrawn over the leech. The senior author routinely teaches patients how to use this device, and in the majority of cases, the patient has been comfortable in completely assuming the leech application task, thus reducing the demand on the nursing staff. In contrast,

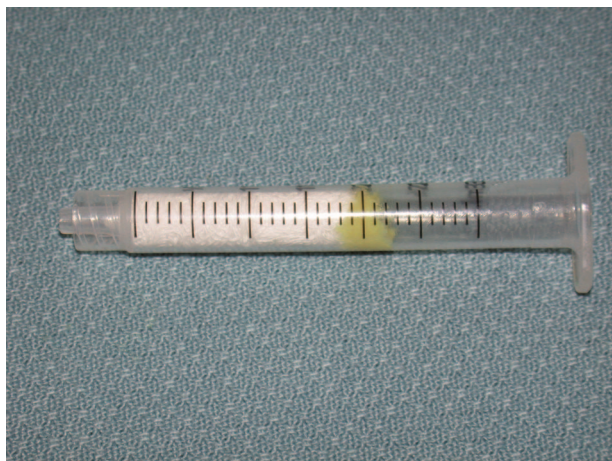

Fig. 1. Petroleum-impregnated gauze.

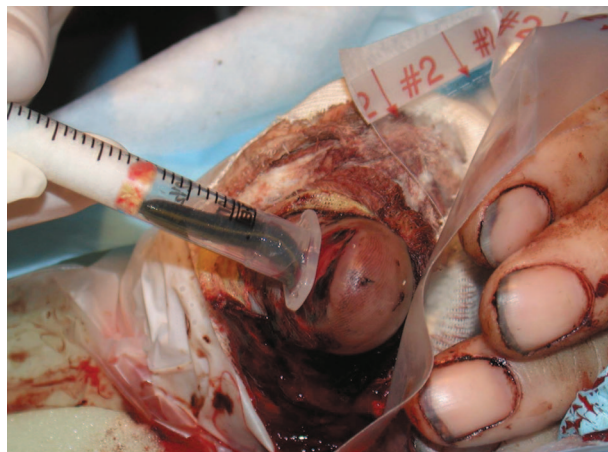


Fig. 2. The leech turns 180 degrees in the applicator, moves down the tube, and attaches to the desired site.

we found it difficult to have patients perform the same leech application task without the use of this 3-cc syringe applicator.

Because leech attachment can be a difficult and time-consuming process, an inexpensive and readily available applicator device that allows easy positioning while minimizing handling of the leech is of great value. This leech applicator encourages rapid leech migration and attachment, and by simplifying the process to involve patients in their own care, it reduces the demand on nursing staff.

DOI: 10.1097/PRS.0b013e318186cd6b

Kodi Azari, M.D.

Christine Fisher, M.D.

Division of Plastic Surgery
University of Pittsburgh School of Medicine
Pittsburgh, Pa.

Correspondence to Dr. Fisher
Division of Plastic Surgery
University of Pittsburgh School of Medicine
664 Scaife Hall
3550 Terrace Street
Pittsburgh, Pa. 15261
fisherc@upmc.edu

REFERENCES

- Whitaker, I. S., Izai, D., Oliver, D. W., Monteath, G., and Butler, P. E. *Hirudo medicinalis* and the plastic surgeon. *Br. J. Plast. Surg.* 57: 348, 2004.
- Batchelor, A. G., Davison, P., and Sully, L. The salvage of congested skin flaps by the application of leeches. *Br. J. Plast. Surg.* 37: 358, 1984.
- Granzow, J. W., Armstrong, M. B., and Panthaki, Z. J. A simple method for the control of medicinal leeches. *J. Reconstr. Microsurg.* 20: 461, 2004.
- MacQuillan, A., Jones, M. E., and Gault, D. Taking a leech to blood: But can you make him drink? *Br. J. Plast. Surg.* 55: 540, 2002.
- Tan, O., and Atik, B. An easy and safe method to apply leeches on flaps: The leech cage. *Plast. Reconstr. Surg.* 113: 466, 2004.

Povidone Iodine versus Chlorhexidine in Skin Antisepsis before Elective Plastic Surgery Procedures: A Randomized Controlled Trial

Sir:

One of the most important risk factors for surgical-site infection is the presence of bacteria in the wound at the time of surgery. Thus, the purpose of preoperative skin preparation is to reduce bacteria on the skin before making an incision.^{1,2}

The antiseptics most commonly used for antisepsis of the operative field include povidone-iodine, chlorhexidine, and their ethanolic solutions.³ The aim of the present study was to compare povidone-iodine and chlorhexidine ethanolic solutions for skin antisepsis before plastic surgery procedures.

Two hundred fifty patients older than 18 years of age, scheduled for elective and clean plastic surgery procedures (i.e., breast reconstruction, mammoplasty, breast prosthesis, abdominoplasty, scar revision, zetaplasty, lipoma exeresis, gynecomasty, and supernumerary mamma) were assigned randomly to the povidone-iodine group ($n = 125$) or the chlorhexidine group ($n = 125$).

The antisepsis was standardized: a vigorous scrub with antiseptic soap, followed by absorption with a sterile towel and painting with an alcohol solution of povidone-iodine 10% or chlorhexidine 0.5% and allowed to dry for 2 minutes. Quantitative skin cultures were obtained from the operative field before scrub, at 2 minutes after painting with antiseptic alcoholic solution, and at the end of surgery.

Samples were plated on hypertonic mannitol agar, selective for staphylococci; on blood agar, to identify hemolytic colonies; and on Sabouraud agar and on eosin-methylene blue agar, selective for fungi and en-

terobacteria, respectively. Staphylococci were identified as coagulase-negative *Staphylococcus* species or *Staphylococcus aureus* on the basis of coagulase testing.

Patients were followed up for 30 days to determine postoperative infection. Centers for Disease Control and Prevention definitions and classification of surgical-site infections were adopted.⁴ Table 1 shows the comparisons between the groups before antisepsis, after 2 minutes, and at the end of surgery, regarding bacterial counts.

Mean operation time was 107.9 minutes in the povidone-iodine group and 97.9 minutes in the chlorhexidine group. The correlation between duration of operation and skin colonization at the end of surgery was significant only for staphylococci, in the povidone-iodine group ($p < 0.001$). *S. aureus* was identified in 17 patients (7.2 percent): 10 patients in the povidone-iodine group and seven in the chlorhexidine group ($p = 0.61$), only before antisepsis.

Four patients (1.6 percent) developed postoperative infection. All of them were allocated to the povidone-iodine group ($p = 0.06$). The infections, in all cases, were classified as superficial incisional surgical-site infections.⁴

Chlorhexidine was significantly more effective than povidone-iodine in reducing the colony counts of coagulase-negative staphylococci at the end of surgery. The superiority of chlorhexidine has several potential explanations. In contrast to iodine-containing compounds, chlorhexidine is not neutralized by contact with blood or other protein-rich biomaterials and has a more prolonged bactericidal action.⁵

The ultimate measure of effectiveness of any skin preparation technique is its ability to prevent postop-

Table 1. Colony-Forming Unit Counts in Povidone-Iodine and Chlorhexidine Groups

Medium	PVP-I vs. Chlorhexidine*		
	Before Antisepsis	2 Minutes after Antisepsis	End of Surgery
HM agar			
PVP-I	82.9 ± 120.1	0.3 ± 1.8	7.9 ± 45.5
Chlorhexidine	86.8 ± 123.6	0.1 ± 0.7	2.7 ± 26.9
z	0.57	0.29	2.72†
			PVP-I > chlorhexidine
Blood agar			
PVP-I	75.4 ± 115.9	1.3 ± 5.7	17.6 ± 64.7
Chlorhexidine	93.8 ± 127.3	0.3 ± 1.3	7.8 ± 46.1
z	1.43	0.51	2.45‡
			PVP-I > chlorhexidine
EMB agar			
PVP-I	0.6 ± 2.7	0.1 ± 1.3	2.8 ± 27.1
Chlorhexidine	24.1 ± 78.3	0.0 ± 0.0	9.0 ± 49.9
z	2.13§	1.00	0.34
	PVP-I < chlorhexidine		
Sabouraud agar			
PVP-I	20.0 ± 65.9	0.3 ± 2.3	0.4 ± 2.4
Chlorhexidine	26.4 ± 79.2	0.2 ± 0.1	2.6 ± 26.8
z	0.47	1.04	1.01

PVP-I, povidone-iodine; HM, hypertonic mannitol; EMB, eosin-methylene blue.

*Antiseptic agent: mean ± SD (colony-forming unit counts); Mann-Whitney test (z).

Statistically significant results: † $p = 0.006$; ‡ $p = 0.014$; § $p = 0.03$.

erative infections.² Despite the fact that all patients with postoperative infection were from the povidone-iodine group, no statistically significant difference in postoperative infection rates was found. However, because staphylococcal skin colonization was significantly lower at the end of surgery when chlorhexidine 0.5% antiseptics was used, we conclude that it is a better choice for skin antiseptics before elective clean plastic surgery procedures.

DOI: 10.1097/PRS.0b013e318186cd7f

Daniela F. Veiga, M.D., Ph.D.

Division of Plastic Surgery
Department of Surgery
Universidade do Vale do Sapucaí
Division of Plastic Surgery
Department of Surgery
Universidade Federal de São Paulo

Carlos A. V. Damasceno, Ph.D.

Department of Microbiology
Universidade do Vale do Sapucaí

Joel Veiga-Filho, M.D.

Ricardo G. Figueiras, M.D.

Roberto B. Vieira, M.D.
Division of Plastic Surgery
Department of Surgery
Universidade do Vale do Sapucaí

Fábio H. Florenzano, Ph.D.

Department of Biochemistry
Universidade do Vale do Sapucaí

Yara Juliano, Ph.D.

Department of Bioesthetics
Universidade do Vale do Sapucaí

Pouso Alegre, Brazil
Universidade Federal de São Paulo

Lydia M. Ferreira, M.D., Ph.D.

Division of Plastic Surgery
Department of Surgery
Universidade Federal de São Paulo
São Paulo, Brazil

Correspondence to Dr. Veiga
Avenida Coronel Armando Rubens Storino
1100, Jardim Paraíso
Pouso Alegre, CEP 37550-000, Brazil
danifveiga@uol.com.br

REFERENCES

1. Garibaldi, R. A., Skolnick, D., Lerer, T., et al. The impact of preoperative skin disinfection on preventing intraoperative wound contamination. *Infect. Control Hosp. Epidemiol.* 9: 109, 1988.
2. Moen, M. D., Noone, M. B., and Kirson, I. Povidone-iodine spray technique versus traditional scrub-paint technique for preoperative abdominal wall preparation. *Am. J. Obstet. Gynecol.* 187: 1434, 2002.
3. Keser, A., Bozkurt, M., Taner, O. F., Yorgancigil, B., Dogan, M., and Sensoz, O. Evaluation of antiseptic use in plastic and hand surgery. *Ann. Plast. Surg.* 55: 490, 2005.
4. Horan, T. C., Gaynes, R. P., Martone, W. J., Jarvis, W. R., and Emori, T. G. CDC definitions of nosocomial surgical site infections 1992: A modification of CDC definitions of surgical wound infections. *Infect. Control Hosp. Epidemiol.* 13: 606, 1992.
5. Chaiyakunapruk, N., Veenstra, D. L., Lipsky, B. A., and Saint, S. Chlorhexidine compared with povidone-iodine solution for vascular catheter-site care: A meta-analysis. *Ann. Intern. Med.* 136: 792, 2002.